

## The surgical management of an exceptional vulvar tumor

Abdi Ahmed Bonahy, Boullale Mohamed Mahmoud,  
Zeinebou Habib, Sidahmed Baba, Sidi Mounir,  
Mohamed Sidahmed, Aissata BA Yaya

### CASE REPORT

A 29-year-old female patient is referred for a vulvar mass, evaluating since one year which has appeared during pregnancy and is associated with depression. We find in her gynecological antecedents: a 4th gesture 4th pare, gave birth seven months ago. The examination finds a patient with good general condition. The gynecological examination showed an enormous mass of the large left lip, this mass is polylobed with umbilical areas of 37.5×20.5 cm and a broad base collar (Figure 1). The examination of the cervix and vagina is normal.

The vaginal examination showed no abnormalities. The results: AgHBS, HIV serology, syphilis, gonococcus and chlamydiae are negative. We suspected a giant condylomatous tumor that had a physical and psychological repercussion on the patient and we decided a surgical excision.

A losangic incision on the large left lip carrying all the tumor which weighed 2400 grams (Figure 2). The

histological analysis of the surgical specimen confirms the benignity of a condylomatous tumor type Buschke–Löwenstein (Figure 3). Follow-up after one-month post-surgery showed good healing (Figure 4).

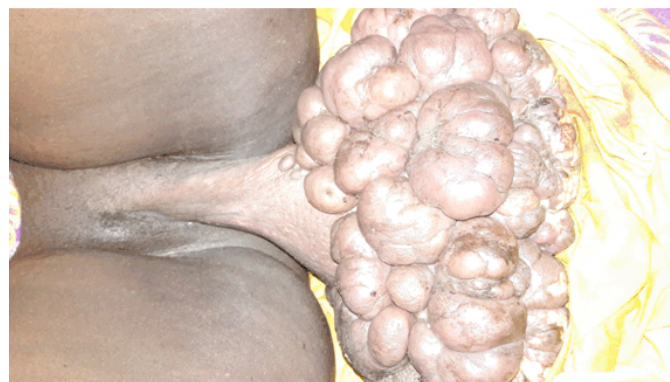

Figure 1: Clinical aspect.

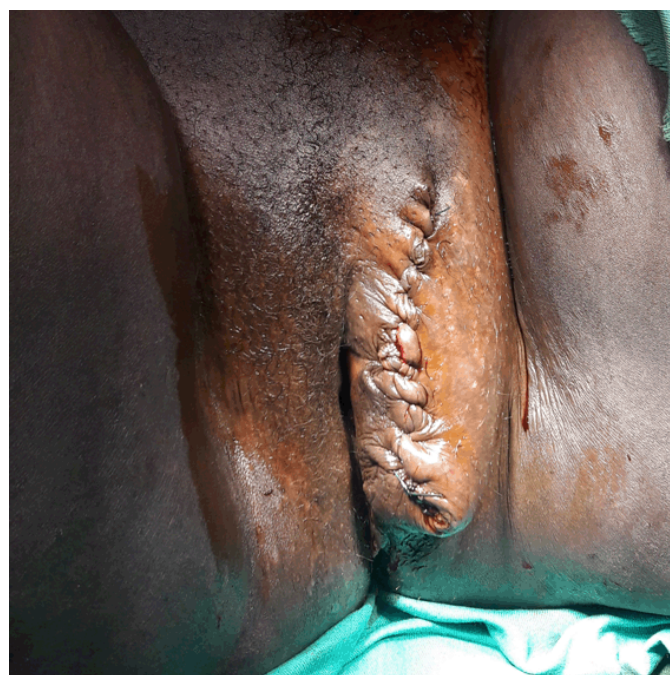

Figure 2: In preoperative.

Abdi Ahmed Bonahy<sup>1</sup>, Boullale Mohamed Mahmoud<sup>2</sup>,  
Zeinebou Habib<sup>2</sup>, Sidahmed Baba<sup>2</sup>, Sidi Mounir<sup>2</sup>, Moham-  
ed Sidahmed<sup>3</sup>, Aissata BA Yaya<sup>4</sup>

**Affiliations:** <sup>1</sup>Head of the Obstetric Gynecology, Department of the Mother and Child Hospital center in Nouakchott, Assistant Professor at the Faculty of Medicine of Nouakchott; <sup>2</sup>Gynecologist at the Mother and Child Hospital Center in Nouakchott; <sup>3</sup>Head of Anesthesia Resuscitation, Department at the Mother and Child Hospital Center, Professor at the Faculty of Medicine of Nouakchott; <sup>4</sup>Gynecologist, Director of the Mother and Child Hospital Center in Nouakchott.

**Corresponding Author:** Dr. Abdi Ahmed Bonahy, Head of Obstetric Gynecology at the mother and child hospital center of Nouakchott-Mauritania, AHU Faculty of Medicine of Nouakchott; Email: abdi\_ahmed74@yahoo.fr

Received: 17 June 2017

Accepted: 26 July 2017

Published: 28 August 2017

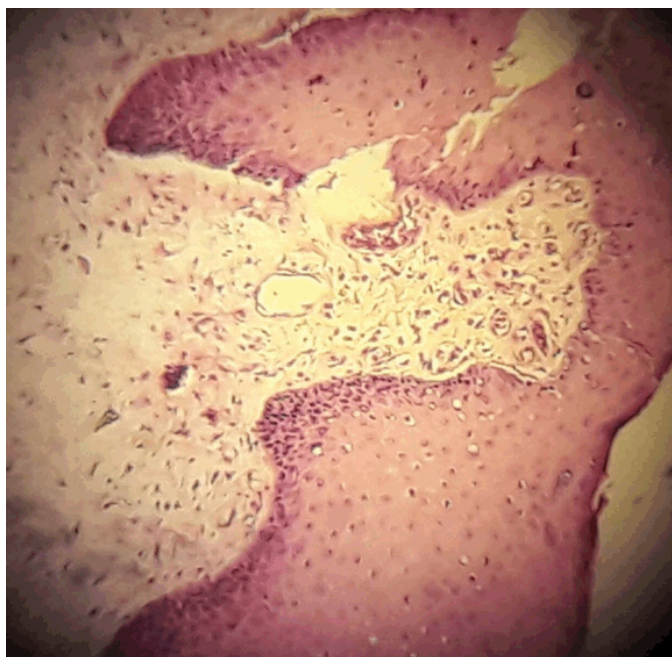

Figure 3: Histological aspect.

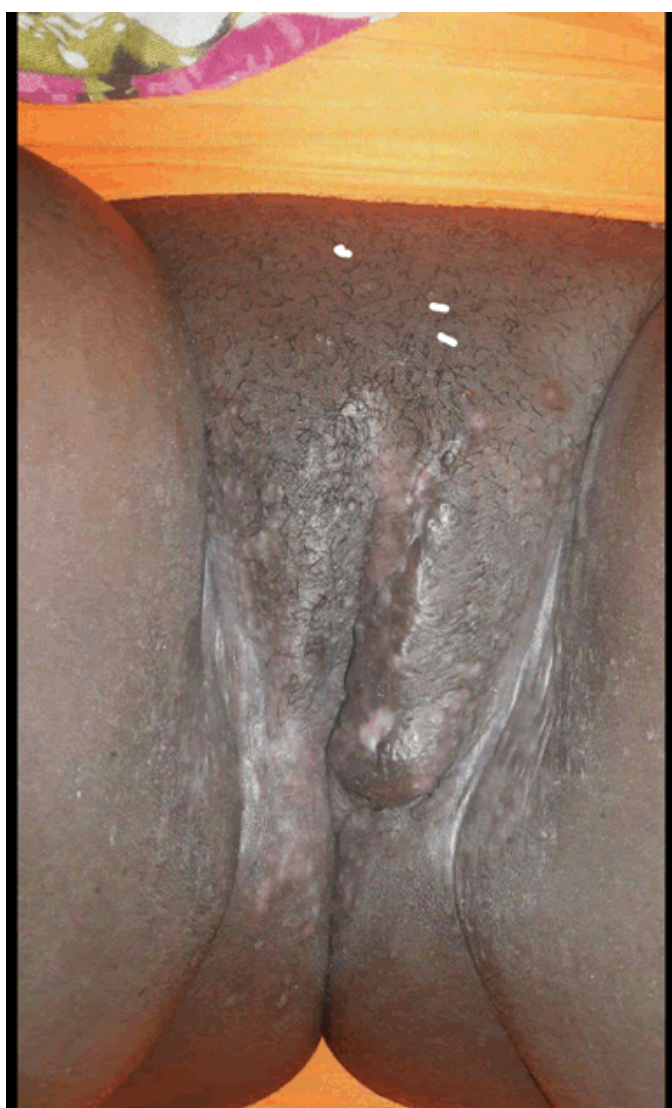


Figure 4: Check after one month.

## DISCUSSION

The giant acuminated condyloma (GAG) is a rare tumor, reported clinically malignant disease, while being histologically benign [1]. The localization in women is vulgar in 90% of cases. In general, it starts on a large lip to extend to the whole of the lips, the vagina, the urethral meatus. In this case, it is a single tumor of the large lip different from the cases published by its healthy base and its weight 2.4 kg. This infection most often affects young people between the ages of 16 and 25 years [2]. The patient, in this case, is a 29-year-old. Clinically, the GAG is a more or less variable tumor of vegetating appearance, verrucous posing a diagnostic problem with CA degenerates of which only complete excision followed by an anatomic-pathological examination will confirm the certain diagnosis [4]. According to Paulstrook and Rabiil, GCA is characterized by papillomatosis. Of a well-differentiated keratinized epithelium associated with a lymphocytic infiltrate [1–4]. The diagnosis of tuberculous lymphadenitis is based on the histological examination of a large, surgical biopsy rather than a circular knife, in order not to wrongly conclude a condyloma [5]. It should be noted that pregnancy is a factor sometimes promoting and even developing AGC [6].

The patient developed this pathology during pregnancy. The evolution can be towards an extension ranging from the surface to the depth. It can be complicated by dermatitis, superinfection, or fistulization to the organs of neighborhood or squarely necrosis [6]. Without forgetting that the transmission of GAG is done mainly by sexual means and also via the water, linen, and other contaminated material [7].

The surgery remains the treatment of first intensity especially in our case where the tumor was accessible [4]. However, the excision of the tumor must be complete leaving a large margin of excision which can sometimes lead to a loss of substance that will later be repaired by a cutaneous graft is possible either in one time or in two stages to avoid the recurrences of primary tumor [4, 5]. The case that we reported the surgical excision was wide and take a distance from the base of the tumor, so it was the radical treatment. The evolution was marked by a good healing without recurrence. Thus, the treatment must therefore remain surgical for the operable cases, in front of the frequency of recurrences and the possible malignant transformation [8]. Regular and prolonged monitoring is required after surgery to detect early recurrence [8]. Chemotherapies and immuno-modulatory treatments deserve better evaluation [4–8].

The laser is sometimes used but has not given a great result [6]. The result of radiotherapy is controversial because it has a harmful effect on healthy tissues by making them anaplastic [4].

## CONCLUSION

This study is an exceptional case of condyloma acuminata vulvar giant, The diagnosis was based on clinical and histological data. The surgical management is based on the wide excision which allows a cure.

\*\*\*\*\*

**Keywords:** Buschke–Löwenstein tumor, Condylomatous tumor, Surgical management, Vaginal examination, Vulvar tumor

### How to cite this article

Bonahy AA, Mahmoud BM, Habib Z, Baba S, Mounir S, Sidahmed M, Yaya AB. The surgical management of an exceptional vulvar tumor. J Case Rep Images Obstet Gynecol 2017;3:43–46.

Article ID: 100030Z08AB2017

\*\*\*\*\*

doi:10.5348/Z08-2017-30-CR-10

\*\*\*\*\*

## Author Contributions

Abdi Ahmed Bonahy – Substantial contributions to conception and design, Revising it critically for important intellectual content, Final approval of the version to be published

Boullale Mohamed Mahmoud – Substantial contributions to conception and design, Drafting the article, Final approval of the version to be published

Zeinebou Habib – Analysis and interpretation of data, Drafting the article, Final approval of the version to be published

Sidahmed Baba – Analysis and interpretation of data, Revising it critically for important intellectual content, Final approval of the version to be published

Sidi Mounir – Acquisition of data, Revising it critically for important intellectual content, Final approval of the version to be published

Mohamed Sidahmed – Substantial contributions to conception and design, Revising it critically for important intellectual content, Final approval of the version to be published

Aissata BA Yaya – Analysis and interpretation of data, Revising it critically for important intellectual content,

Final approval of the version to be published

## Guarantor

The corresponding author is the guarantor of submission.

## Conflict of Interest

Authors declare no conflict of interest.

## Copyright

© 2017 Abdi Ahmed Bonahy et al. This article is distributed under the terms of Creative Commons Attribution License which permits unrestricted use, distribution and reproduction in any medium provided the original author(s) and original publisher are properly credited. Please see the copyright policy on the journal website for more information.

## REFERENCES

1. Strock P, Barrioz T, Lauroy J, et al. Aspect échoendoscopique d'un condylome acuminé géant rectal malin (tumeur de Buschke–Löwenstein). [Article in French] Gastroenterol Clin Biol 2004;28:801–3.
2. Trombetta LJ, Place RJ. Giant condyloma acuminatum of the anorectum: Trends in epidemiology and management— Report of a case and review of the literature. Dis Colon Rectum 2001 Dec;44(12):1878–86.
3. Chu QD, Vezeridis MP, Libbey NP, Wanebo HJ. Giant condyloma acuminatum (Buschke–Löwenstein tumor) of the anorectal and perianal regions: Analysis of 42 cases. Dis Colon Rectum 1994 Sep;37(9):950–7.
4. Rabii R, Joual A, Bellabidia B, et al. Giant scrotal condyloma acuminata: A case report. [Article in French]. Ann Urol (Paris) 2001 Jan;35(1):67–70.
5. Dauendorffer JN, Cavelier-Balloy B, Bagot M, Renaud-Vilmer C. Male genital Buschke–Löwenstein tumour. [Article in French]. Ann Dermatol Venereol 2016 Nov;143(11):796–8.
6. Qarro A, Ait Ali A, Choho A, Alkandry S, Borki K. Anorectal Buschke–Löwenstein tumor: Three cases report. [Article in French]. Ann Chir 2005 Feb;130(2):96–100.
7. Rimtebaye K, Danki Sillong F, Zarif Agah Tashkand A, Kaboro M, Niang L, Gueye SM. Tumeur de Buschke–Löwenstein: à propos de 8 cas et revue de la littérature. [Article in French]. Afr J Urol 2016 22(4):319–24.
8. Lévy A, Lebbe C. Buschke–Löwenstein tumour: Diagnosis and treatment. [Article in French]. Ann Urol (Paris) 2006 Jun;40(3):175–8.

Access full text article on  
other devices



Access PDF of article on  
other devices

