

## CASE REPORT

## PEER REVIEWED | OPEN ACCESS

# Large uterine leiomyoma presenting as pseudo-Meigs' syndrome with an elevated CA 125: Case report and literature review

Jake Alan Gibbons

## ABSTRACT

**Introduction:** Uterine leiomyomas presenting as pseudo-Meigs' syndrome with an elevated CA 125 are rare and pose a diagnostic challenge for physicians. **Case Report:** A 35-year-old GoPo presented to the emergency department with a chief complaint of abdominal swelling and weight gain beginning one month ago. Laboratory work was significant for an elevated CA 125. She was found to have a large mass originating from her uterus. Following resection of the mass, her symptoms resolved. Pathology of the mass came back as a uterine leiomyoma. **Conclusion:** Generally, findings of ascites, a pelvic mass, and an elevated CA 125 in a female suggests a diagnosis of ovarian cancer. However, as demonstrated by our case and others, benign causes such as Meigs' syndrome and pseudo-Meigs' syndrome should also be considered. Surgery is the mainstay of treatment in pseudo-Meigs' syndrome. Resolution of the ascites and hydrothorax occurs spontaneously following resection of the tumor.

**Keywords:** Ascites, CA 125, Gynecology, Leiomyoma, Pseudo-Meigs' syndrome

## How to cite this article

Gibbons JA. Large uterine leiomyoma presenting as pseudo-Meigs' syndrome with an elevated CA 125: Case report and literature review. J Case Rep Images Obstet Gynecol 2019;5:100046Z08JG2019.

Article ID: 100046Z08JG2019

\*\*\*\*\*

doi: 10.5348/100046Z08JG2019CR

## INTRODUCTION

Meigs' syndrome is the triad of a benign ovarian fibroma or thecoma combined with ascites and hydrothorax [1]. A clinically similar yet distinct pathological entity is pseudo-Meigs' syndrome. Like Meigs' syndrome, pseudo-Meigs' syndrome presents with ascites and hydrothorax. However, unlike Meigs' syndrome, pseudo-Meigs' syndrome is associated with non-thecoma, non-fibroma ovarian tumors or uterine leiomyomas [1]. Ovarian tumors reported in pseudo-Meigs' syndrome include: strumaovarii tumors, germ cell tumors, ovarian metastases from gastric or colon cancer, and serous or mucinous cystadenomas [2]. The uterine leiomyoma, however, is the most commonly reported tumor in cases of pseudo-Meigs' syndrome [3]. Leiomyomas have an incidence of 20-50% in females over the age of 30, but only rarely do they present with ascites and hydrothorax [1]. On its own, pseudo-Meigs' syndrome is a rare diagnosis. A concomitant elevation in cancer antigen 125 (CA 125) in a patient presenting with pseudo-Meigs' syndrome is an even more uncommon finding [4-7]. We report a case of pseudo-Meigs' syndrome in a 35-year-old female who was also found to have a markedly elevated CA 125. Additionally, a literature review was

Jake Alan Gibbons

**Affiliation:** Student, School of Medicine, The University of Texas Medical Branch, Galveston, Texas, United States.

**Corresponding Author:** Jake Alan Gibbons, 500 Seawall Blvd Unit 1109, Galveston, Texas 77550, United States; Email: jagibbon@utmb.edu

Received: 04 January 2019

Accepted: 25 March 2019

Published: 02 May 2019

performed and past cases of pseudo-Meigs' syndrome were identified. Data from those cases is presented in the discussion section of this paper following the case report.

## CASE REPORT

A 35-year-old GoPo who presented to the emergency department with a chief complaint of abdominal swelling and weight gain beginning one month ago. She reported increasing abdominal pain, abdominal swelling, nausea, and vomiting. She denied chest pain, shortness of breath, heat or cold intolerance, palpitations, and any motor or sensory deficits. She had no history of cancer. Her past surgical history was significant for an exploratory laparotomy sixteen years ago due to an abdominal stab wound.

On physical examination, her abdomen was distended and mildly tender to palpation in all four quadrants. A fluid wave was present. A large mass was palpated in the left lower quadrant. No other abnormalities were observed on physical examination. Her blood work was significant for a leukocyte count of  $12.8 \times 10^3/\mu\text{L}$  and a markedly elevated CA 125 level of 272.9 U/ml. Given the elevated CA 125, combined with the ascites and mass on physical examination, a presumptive diagnosis of ovarian carcinoma was made.

A CT scan was ordered, which demonstrated a large intra abdominal mass measuring 28.8 cm and significant ascites. The mass contained both cystic and solid components, as well as internal vascularity. Omental carcinomatosis was also present.

The patient was taken to the operating room for a planned exploratory laparotomy, lysis of adhesions, omentectomy, excision of intra abdominal mass, hysterectomy, and bilateral salpingo-oophorectomy. An incision was made from the diploid process to the symphysis pubis. The wound was deepened using electrocautery. Upon entry into the abdomen, two ventral hernias were identified. The hernia sacs were divided and sent to pathology. Two liters of intra abdominal fluid was aspirated. Peritoneal washings were sent to pathology.

The mass was identified. It was closely adherent to the anterior abdominal wall, and also involved the omentum, sigmoid colon, and two large areas of small bowel. It was dissected from the anterior abdominal wall and the two segments of small bowel. Both of the segments of small bowel were resected. Two side-to-side functional end-to-end anastomoses were performed to close the common enterotomy.

A portion of the sigmoid mesentery involving the mass was removed. The tumor, which appeared to originate from the uterine fundus, was completely resected and sent to pathology. A total abdominal hysterectomy and bilateral salpingo-oophorectomy were performed. The abdomen was examined for additional sites of metastasis, but none were identified. The abdomen was closed using #1 looped Polydioxanone sutures. The wound

was irrigated with saline and subsequently closed with a skin stapler. The patient tolerated the procedure well and was extubated without complications. Pathology demonstrated that the mass was an aggressive-behaving uterine leiomyoma (Figure 1). Additionally, ascitic cytology was negative for malignant cells.

## DISCUSSION

Findings of ascites, a pelvic mass, and an elevated CA 125 in a female carry a grim prognosis, most likely that of an ovarian carcinoma [8, 9]. However, as demonstrated by this case and others, benign etiologies must also be considered on the differential diagnosis [9]. Cases of Meigs' syndrome and pseudo-Meigs' syndrome with elevations in CA 125 have been reported, which should prompt physicians to consider these diagnoses as well [9–11]. Furthermore, an elevated CA 125 is not 100% specific for ovarian carcinoma [12]. Pelvic inflammatory disease, pregnancy, endometriosis, benign ovarian tumors, and uterine leiomyomas can cause CA 125 to become elevated [13]. In cases of Meigs' syndrome, it has been conjectured that mesothelial expression of CA 125, as opposed to expression by the fibroma, is the cause of the elevation [10, 11]. In pseudo-Meigs' syndrome, peritoneal inflammation has been implicated as the cause of the elevation in CA 125 [9].

In both Meigs' syndrome and pseudo-Meigs' syndrome, spontaneous resolution of the pleural effusion and ascites occurs following resection of the underlying tumor [14]. The cause of the ascites and hydrothorax in both Meigs' syndrome and pseudo-Meigs' syndrome is not entirely known, but likely multifactorial. It has been reported that, intraoperatively, cutting a uterine leiomyoma caused fluid leakage from myometrial cysts within the tumor [9]. Thus, it is possible that the fluid production is the result of cystic degeneration of the tumor [15]. In addition to fluid from the tumor itself, peritoneal fluid production is also a likely factor in the production of the ascites. Mechanical irritation of the peritoneum from the tumor in addition to pressure from pre-existing ascites causes peritoneal inflammation, which results in further fluid production [16]. The development of pleural effusion in these syndromes is thought to be a result of transdiaphragmatic transport of the ascitic fluid into the thorax through intercellular gaps [9].

A comprehensive review of the English literature using PubMed and Medline was performed, which resulted in 21 cases describing uterine leiomyomas presenting as pseudo-Meigs' syndrome with an elevated CA 125 (Table 1). Review of the literature indicates that the mean age of presentation was 40 years (22–66 years). The majority of patients, 15 of 21 cases, presented with abdominal distention. Additionally, in 8 of 21 cases, patients reported dyspnea. Other symptoms less commonly reported include: nausea, vomiting, dysuria, and urinary frequency. The average CA 125 level of the 21 cases was

Table 1: Literature review of uterine leiomyomas presenting as pseudo-Meigs' syndrome with an elevated CA 125

Author	Year	Age	Symptoms	CA 125 (U/mL)	Tumor size	Presence of ascites	Presence of pleural effusion	Type of surgery	Recurrence
Frank et al. [17]	1973	66	Dyspnea, fatigue, palpitations, orthopnea, and anorexia	NS	18x16x13 cm	Y	Y, right side	EX LAP and removal of tumor	NS
Rush [18]	1976	47	8 months of weakness with exertion, intermittent painless abdominal swelling, constipation, lethargy, blood streaked stools	NS	20 cm in diameter	Y	Y, left side	EX LAP, TAH, BSO, colon polypectomy	NS
Handler et al. [19]	1982	35	2 months of progressively increasing dyspnea, dysmenorrhea, deep dyspareunia	NS	9x9 cm	Y	Y, right side	EX LAP and excision of the mass	No recurrence after 1 year
Buckshee et al. [20]	1990	46	Progressive abdominal distention and loss of appetite for 1.5 months	NS	20x20 cm	Y	Y, bilateral	TAH with myomectomy and RSO	No recurrence, but time not specified
Ollendorf et al. [5]	1997	31	2 year history of increasing abdominal girth and six months of progressive shortness of breath	301	27x18x13 cm	Y	Y, right side	EX LAP and myomectomy	No recurrence after 8 months
Brown et al. [14]	1998	31	Dyspnea, abdominal swelling, intermittent difficulty in passing urine, 6kg weight loss	83	17x11.5x8.5 cm	Y	Y, right side	NS	No recurrence after 18 months
Dunn et al. [7]	1998	46	Nausea, vomiting, diarrhea, tachypnea	254	15x30x18 cm	Y	Y, right side	EX LAP, subtotal abdominal hysterectomy, BSO, omentectomy, and lymph node sampling	NS
Domingo et al. [6]	1998	46	Menorrhagia for several years, 2 months of fatigue and malaise, 3 weeks of pedal edema, abdominal swelling, shortness of breath	317	20 cm in diameter	Y	Y, bilateral	TAH with BSO	NS
Migishima et al. [21]	2000	51	Gradual abdominal distention for 3 years, progressive dyspnea for 5 months	820	12.3x24.3x20.5 cm	Y	Y, left side	EX LAP, TAH, BSO	No recurrence after 4 months
Amant et al. [9]	2001	39	Abdominal swelling	785	30x30x15 cm	Y	Y, left side	TAH	NS

Table 1: (Continued)

Kebapci et al. [22]	2002	38	1 week of low back pain, abdominal distention, weakness, and loss of appetite	281	9x10x10.5 cm	Y	Y, left side	EX LAP and excision of the mass, aspiration of the ascitic fluid, omentectomy, and appendectomy	NS
Weise et al. [23]	2002	27	Increasing abdominal girth for 2 months	1854	7x8x6 cm	Y	Y, right side	EX LAP and myomectomy	No recurrence after 3 months
Weinrach et al. [24]	2004	40	2 year history of increasing abdominal distention and several months of progressive shortness of breath	734	19x11x10 cm	Y	Y, right side	TAH with BSO	No recurrence after 6 months
Landrum et al. [25]	2008	47	Symptoms of upper respiratory infection, worsening anasacra and profound increase in abdominal girth	475	20x22 cm	Y	Y, bilateral	EX LAP, TAH, BSO, pelvic and para-aortic lymphadenectomy	NS
Ricci et al. [26]	2009	35	Abdominal distention 2 days after a spontaneous vaginal delivery	231.4	15x10x8.5 cm	Y	NS	EX LAP and removal of pedunculated mass	No recurrence after 3 years
Chourmouzi et al. [3]	2010	41	12 month history of abdominal swelling, discomfort, urinary frequency and incontinence	436.7	13x16 cm	Y	NS	EX LAP and excision of the mass	NS
Makris et al. [27]	2012	26	Noticed pelvic mass	93.9	11x8.3x 10.2 cm	Y	NS	EX LAP and open myomectomy	No recurrence after 2 months
Yip et al. [13]	2013	41	Abdominal fullness and prolonged menstrual periods for 3 years	939.7	12x11x7.8 cm	Y	N	EX LAP and removal of mass	NS
Oguma et al. [28]	2014	50	3 month history of shortness of breath	218	14x8x7 cm	Y	Y, right side	TAH with BSO	Not specified
Seo et al. [29]	2014	22	10 days of painless abdominal distention	450	8.9x5.2 cm	Y	N	EX LAP and removal of mass	No recurrence after 5 years
Dong et al. [12]	2015	37	Right lower abdominal dull pain for 2 years, abdominal distention for 6 days, nausea	920.4	20x18x10 cm	Y	Y, bilateral	EX LAP and TAH	No recurrence after 82 months

Y- Yes

N- No

NS- Not specified

EX LAP- Exploratory laparotomy

TAH- Total abdominal hysterectomy

BSO- Bilateral salpingo-oophorectomy

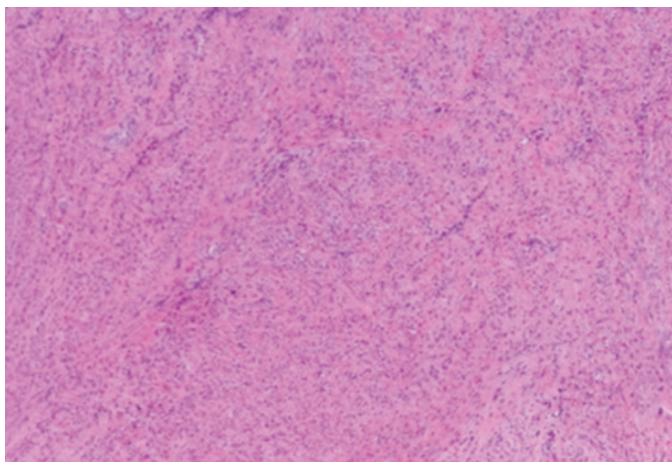


Figure 1: Pathological examination of the mass was consistent with a uterine leiomyoma.

541 U/mL (83 U/mL-1854 U/mL). Ascites was present in all 21 cases, and hydrothorax was reported in 16 of the 21 cases. All patients were treated surgically, with no reported cases of tumor recurrence.

## CONCLUSION

Uterine leiomyomas presenting as pseudo-Meigs' syndrome with an elevated CA 125 are exceedingly rare. In a patient with a clinical presentation consistent ovarian cancer with the added finding of an elevated CA 125, benign etiologies such as Meigs' syndrome and pseudo-Meigs' syndrome should also be considered in the differential diagnosis. Surgery is the mainstay of treatment in pseudo-Meigs' syndrome. Resolution of the ascites and hydrothorax occurs spontaneously following resection of the tumor. No cases of recurrence have been reported in the literature.

## REFERENCES

1. Meigs JV. Fibroma of the ovary with ascites and hydrothorax; Meigs' syndrome. *Am J Obstet Gynecol* 1954;67(5):962-85.
2. Zannoni GF, Gallotta V, Legge F, Tarquini E, Scambia G, Ferrandina G. Pseudo-Meigs' syndrome associated with malignant struma ovarii: A case report. *Gynecol Oncol* 2004;94(1):226-8.
3. Chourmouzi D, Papadopoulou E, Drevelegas A. Magnetic resonance imaging findings in pseudo-Meigs' syndrome associated with a large uterine leiomyoma: A case report. *J Med Case Rep* 2010;4:120.
4. Lee MJ, Kazer RR. Massive ascites after leuprolide acetate administration for the treatment of leiomyomata uteri. *Fertil Steril* 1992;58(2):416-8.
5. Ollendorff AT, Keh P, Hoff F, Lurain JR, Fishman DA. Leiomyoma causing massive ascites, right pleural effusion and respiratory distress: A case report. *J Reprod Med* 1997;42(9):609-12.

6. Domingo P, Montiel JA, Monill JM, Prat J. Pseudo-Meigs syndrome with elevated CA 125 levels. *Arch Intern Med* 1998;158(12):1378-9.
7. Dunn JS Jr, Anderson CD, Method MW, Brost BC. Hydropic degenerating leiomyoma presenting as pseudo-Meigs syndrome with elevated CA 125. *Obstet Gynecol* 1998;92(4 Pt 2):648-49.
8. Gal D, Buchsbaum HJ, Voet R, Forney JP. Massive ascites with uterine leiomyomas and ovarian vein thrombosis. *Am J Obstet Gynecol* 1982;144(6):729-31.
9. Amant F, Gabriel C, Timmerman D, Vergote I. Pseudo-Meigs' syndrome caused by a hydropic degenerating uterine leiomyoma with elevated CA 125. *Gynecol Oncol* 2001;83(1):153-7.
10. Lin JY, Angel C, Sickel JZ. Meigs syndrome with elevated serum CA 125. *Obstet Gynecol* 1992;80(3 Pt 2):563-6.
11. Timmerman D, Moerman P, Vergote I. Meigs' syndrome with elevated serum CA 125 levels: Two case reports and review of the literature. *Gynecol Oncol* 1995;59(3):405-8.
12. Dong R, Jin C, Zhang Q, Yang X, Kong B. Cellular leiomyoma with necrosis and mucinous degeneration presenting as pseudo-Meigs' syndrome with elevated CA125. *Oncol Rep* 2015;33(6):3033-7.
13. Yip HK, Huang LW, Lin YH, Hwang JL. Massive ascites caused by a large pedunculated subserosal uterine leiomyoma that has feeding arteries from peripheral tissues and exhibits elevated CA125: A case report of atypical pseudo-Meigs' syndrome. *J Obstet Gynaecol* 2014;34(1):107.
14. Brown RS, Marley JL, Cassoni AM. Pseudo-Meigs' syndrome due to broad ligament leiomyoma: A mimic of metastatic ovarian carcinoma. *J Clin Oncol (R Coll Radiol)* 1998;10(3):198-201.
15. Clement PB. Pure mesenchymal tumors. In: Clement PB, Young RH. *Tumors and Tumorlike Lesions of the Uterine Corpus and Cervix*. New York: Churchill Livingstone; 1993. p. 285-328.
16. Jimerson SD. Pseudo-Meigs's syndrome. An unusual case with analysis of the effusions. *Obstet Gynecol* 1973;42(4):535-7.
17. Frank N, Frank MJ. Uterine tumour mimicking Meigs' syndrome (intractable heart failure). *J Med Soc N J* 1978;70(1):17-8.
18. Rush BM. Leiomyoma of the uterus, ascites and hydrothorax (pseudo-Meig's syndrome). *J La State Med Soc* 1976;128(1):7-8.
19. Handler CE, Fray RE, Snashall PD. Atypical Meigs' syndrome. *Thorax* 1982;37(5):396-7.
20. Buckshee K, Dhond AJ, Mittal S, Bose S. Pseudo-Meigs' syndrome secondary to broad ligament leiomyoma: A case report. *Asia Oceania J Obstet Gynaecol* 1990;16(3):201-5.
21. Migishima F, Jobo T, Hata H, et al. Uterine leiomyoma causing massive ascites and left pleural effusion with elevated CA 125: A case report. *J Obstet Gynecol Res* 2000;26(4):283-7.
22. Kebapci M, Aslan O, Kaya T, Yalcin OT, Ozalp S. Pedunculated uterine leiomyoma associated with pseudo-Meigs' syndrome and elevated CA-125 level: CT features. *Eur Radiol* 2002;12 Suppl 3:S127-9.

23. Weise M, Westphalen S, Fayyazi A, Emons G, Krauss T. Pseudo-Meigs syndrome. Uterine leiomyoma with bladder attachment associated with ascites and hydrothorax – a rare case of a rare syndrome. *Onkologie* 2002;25(5):443–6.
24. Weinrach DM, Wang KL, Keh P, Sambasiva Rao M. Pathologic quiz case: A 40-year-old woman with a large pelvic mass, ascites, massive right hydrothorax and elevated CA125. *Arch Pathol Lab Med* 2004;128(8):933–4.
25. Landrum LM, Rutledge TL, Osunkoya AO, Mannel R. Uterine leiomyoma with associated pseudo-Meigs syndrome mimicking ovarian carcinoma. *J Okla State Med Assoc* 2008;101(2):38–9.
26. Ricci G, Inglese S, Candiotta A, et al. Ascites in puerperium: A rare case of atypical pseudo-Meigs' syndrome complicating the puerperium. *Arch Gynecol Obstet* 2009;280(6):1033–7.
27. Makris A, Talmor A, Moyle P, Majmudar T, Abdel-Rahman H. Parasitic fibroid and pseudo-Meigs' syndrome: Co-existence of two rare entities. *J Obstet Gynaecol* 2012;32(4):408–9.
28. Oguma T, Yamasaki N, Nakanishi K, et al. Pseudo-Meigs' syndrome associated with hydropic degenerating uterine leiomyoma: A case report. *J Obstet Gynaecol Res* 2014;40(4):1137–40.
29. Seo M, Sung JY, Cho HJ, et al. Ascites associated with uterine leiomyoma in a 22-year-old woman with systemic lupus erythematosus. *Lupus* 2014;23(11):1207–10.

\*\*\*\*\*

**Author Contributions**

Jake Alan Gibbons – Conception of the work, Design of the work, Acquisition of data, Analysis of data, Interpretation

of data, Drafting the work, Revising the work critically for important intellectual content, Final approval of the version to be published, Agree to be accountable for all aspects of the work in ensuring that questions related to the accuracy or integrity of any part of the work are appropriately investigated and resolved

**Guarantor of Submission**

The corresponding author is the guarantor of submission.

**Source of Support**

None.

**Consent Statement**

Written informed consent was obtained from the patient for publication of this article.

**Conflict of Interest**

Authors declare no conflict of interest.

**Data Availability**

All relevant data are within the paper and its Supporting Information files.

**Copyright**

© 2019 Jake Alan Gibbons et al. This article is distributed under the terms of Creative Commons Attribution License which permits unrestricted use, distribution and reproduction in any medium provided the original author(s) and original publisher are properly credited. Please see the copyright policy on the journal website for more information.

Access full text article on other devices



Access PDF of article on other devices





INTERNATIONAL JOURNAL OF  
CASE REPORTS AND IMAGES



VIDEO JOURNAL OF  
CLINICAL RESEARCH



VIDEO JOURNAL OF  
BIOMEDICAL SCIENCE



INTERNATIONAL JOURNAL OF  
HEPATOBIILIARY AND  
PANCREATIC DISEASES



INTERNATIONAL JOURNAL OF  
BLOOD TRANSFUSION AND  
IMMUNOHEMATOLOGY



EDORIUM JOURNAL OF  
OPHTHALMOLOGY



**Submit your manuscripts at**  
[www.edoriumjournals.com](http://www.edoriumjournals.com)



EDORIUM JOURNAL OF  
MEDICINE



EDORIUM JOURNAL OF  
CARDIOTHORACIC AND  
VASCULAR SURGERY



JOURNAL OF CASE REPORTS  
AND IMAGES IN ORTHOPEDICS  
AND RHEUMATOLOGY



EDORIUM JOURNAL OF  
PSYCHOLOGY



EDORIUM JOURNAL OF  
CELL BIOLOGY



JOURNAL OF CASE REPORTS AND IMAGES IN  
DENTISTRY



EDORIUM JOURNAL OF  
CANCER



EDORIUM JOURNAL OF  
PSYCHIATRY



JOURNAL OF CASE REPORTS AND  
IMAGES IN INFECTIOUS DISEASES



EDORIUM JOURNAL OF  
ANATOMY AND EMBRYOLOGY



EDORIUM JOURNAL OF  
SURGERY



JOURNAL OF CASE REPORTS  
AND IMAGES IN PATHOLOGY



EDORIUM JOURNAL OF  
ANESTHESIA