

CASE REPORT

PEER REVIEWED | OPEN ACCESS

Xanthogranulomatous salpingitis and its association with endometriosis: A case report and review of the literature

Marie Claire Vassallo, Mandy Collict, Kelvin Cortis,
James DeGaetano, Mark Formosa

ABSTRACT

A case of xanthogranulomatous salpingitis is presented in a 36-year-old woman with a longstanding history of chronic pelvic pain on a background of endometriosis. The presentation of endometriosis in this case is that of hemorrhagic ascites which is a rare occurrence. Xanthogranulomatous salpingitis is a rare form of chronic inflammation involving the fallopian tube, and it is characterized by the presence of lipid-laden macrophages and other chronic inflammatory cells within the wall of the fallopian tube. There are only a few cases of xanthogranulomatous inflammation affecting the female genital tract which are reported in the medical literature.

Keywords: Endometriosis, Fallopian tube, Hemorrhagic ascites, Xanthogranulomatous salpingitis

How to cite this article

Vassallo MC, Collict M, Cortis K, DeGaetano J, Formosa M. Xanthogranulomatous salpingitis and its association with endometriosis: A case report and review of the literature. J Case Rep Images Obstet Gynecol 2019;5:100050Z08MV2019.

Marie Claire Vassallo¹, Mandy Collict², Kelvin Cortis³, James DeGaetano⁴, Mark Formosa¹

Affiliations: ¹Department of Obstetrics & Gynaecology, Mater Dei Hospital, Malta, Dun Karm Street, Msida, Malta; ²Department of Obstetrics & Gynaecology, Mater Dei Hospital, Malta; ³Medical Imaging Department, Mater Dei Hospital, Malta; ⁴Department of Pathology, Mater Dei Hospital, Malta.

Corresponding Author: Dr. Marie Claire Vassallo (Registrar), Department of Obstetrics & Gynaecology, Mater Dei Hospital, Malta, Dun Karm Street, Msida, Malta; Email: vassallomarieclaire@gmail.com

Received: 19 March 2019
Accepted: 12 April 2019
Published: 05 August 2019

Article ID: 100050Z08MV2019

doi: 10.5348/100050Z08MV2019CR

INTRODUCTION

Xanthogranulomatous inflammation is a rare, chronic form of granulomatous inflammation which is destructive to the normal tissues of affected organs [1–4]. The organ that is most affected by this uncommon process is the kidney followed by the gallbladder [1, 5], however xanthogranulomatous inflammation has been reported to occur in other organs like the stomach, salivary glands, anorectal area, bone, urinary bladder, testis, and epididymis [3, 4, 6–8]. There are a few reported cases in the literature involving the female genital tract and most often it has been found to affect the endometrium but involvement of the myometrium, cervix, vagina, fallopian tube, and ovary have all been documented [1–3, 6].

It is histologically characterized by the complete or partial replacement of the mucosa by granulation tissue with an infiltration of lipid-laden foamy macrophages (foamy histiocytes containing small dark nuclei within a clear cytoplasm) together with an infiltrate of plasma cells, lymphocytes, neutrophils, eosinophils, and multinucleated giant cells [4, 9, 10]. It has been proposed that this process is seen following inflammation, infection, obstruction, hemorrhage, and necrosis [3, 9].

The case reported here involves xanthogranulomatous salpingitis which occurred on a background of extensive endometriosis. This patient also presented with persistent ascites which is the persistent accumulation of fluid within the peritoneal cavity and usually occurs secondary to liver disease, congestive cardiac failure, and nephrotic syndrome. However, ascites can also be attributed to gynecological causes including ovarian tumors, ovarian hyperstimulation syndrome, Meigs' syndrome, and pelvis tuberculosis. Ascites secondary to endometriosis is uncommonly encountered and represents an inflammatory exudate.

CASE REPORT

Here we present a 36-year-old Maltese lady who first presented in 2015 with a history of abdominal and pelvic pain, dysmenorrhea, and primary infertility. Past medical history revealed a history of pericarditis and pericardial effusion two years prior, for which she was thoroughly investigated however no cause was identified. The patient denied any associated respiratory, urinary, or bowel problems.

An ultrasound scan was performed and pelvic ascites was detected with no identifiable cause. Fluid in Morrison's pouch was also noted. Further imaging was carried out and on computed tomography (CT) thorax, abdomen, pelvis; fluid in pelvis, and paracolic gutters was confirmed and a 3.7 cm by 4.1 cm by 4.3 cm cystic lesion in the right adnexa was also noted.

Initial blood results showed normal inflammatory markers and an elevated CA125 of 62.6 U/ml (reference range up to 30.2 U/ml). Ascitic tapping was performed and the turbid blood-stained fluid obtained was sent for biochemistry, cytology, and culture. Microscopy revealed numerous hemosiderin-laden macrophages, together with small clusters of mesothelial cells, lymphocytes, neutrophils, and eosinophils. An exudative process was confirmed by biochemistry. Cytology and culture were negative.

In view of episodes of low grade fever which accompanied abdominal pain, the patient was also tested for Familial Mediterranean Fever but no mutations in the pyrin gene were identified.

The ascites persisted and all investigations carried out yielded no actual cause. In July 2017, a magnetic resonance (MR) scan of the liver, spleen, pancreas, and pelvis was performed and moderate amount of ascites compatible with blood products and several peritoneal nodules were noted (Figures 1 and 2). The main differential diagnosis at this stage was that of peritoneal endometriosis with recurrent hemorrhagic ascites. A diagnostic laparoscopy was then performed and moderate hemorrhagic ascites together with dense adhesions in the pouch of Douglas and to the abdominal wall were noted. Multiple biopsies were taken from the right ovary, left fallopian tube, pelvic peritoneum, right iliac fossa, and deposits in the abdominal wall. Histology from the above specimens revealed widespread endometriosis and xanthogranulomatous salpingitis of the left fallopian tube (Figure 3). The patient was then subsequently treated with a six-month course of goserelin, a gonadotropin releasing hormone agonist.

A second look laparoscopy was performed in March 2018, and multiple thick adhesions with hemorrhagic ascites in pelvis and in pockets between adhesions in the paracolic gutters were noted. Several omental adhesions were also found involving the liver surface. Bilateral salpingectomy and appendectomy were performed and the histology result showed endometriosis.

Outcome and follow-up

The patient was referred for assisted reproductive technology.

DISCUSSION

Xanthogranulomatous inflammation has been linked to multiple etiologies. Proposed causes and risk factors which have been implicated in the pathogenesis,

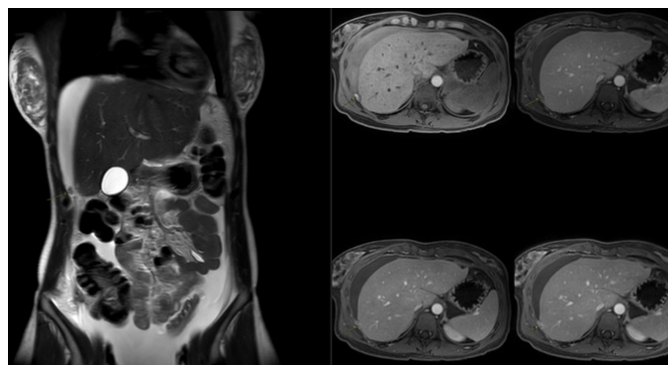


Figure 1: An MR image is showing a peritoneal endometriosis nodule and ascites.

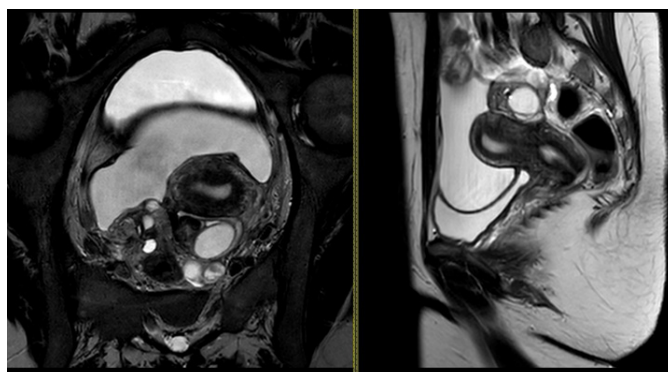


Figure 2: An MR image is showing the endometriomas around the uterus.

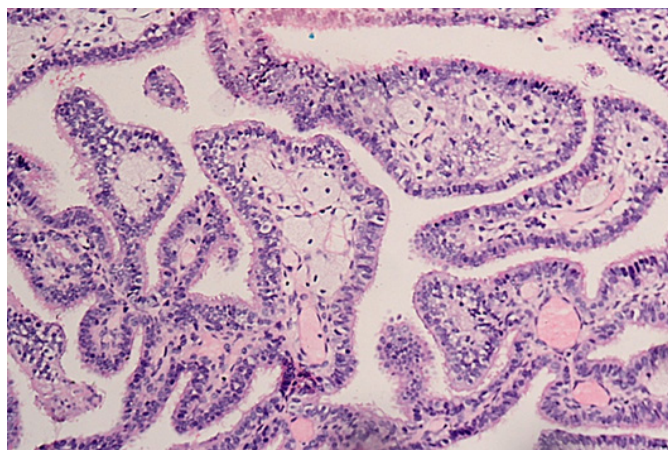


Figure 3: An image is showing fronds from the fallopian tube broadened by the presence of foamy histiocytes within the stroma.

sometimes occurring in combination, include bacterial infections, ineffective antibiotic therapy, endometriosis, immunosuppression, chronic inflammatory conditions, luminal obstruction, leiomyoma, abnormalities involving lipid metabolism, ineffective clearance of bacteria by phagocytes, the use of an intrauterine contraceptive device, radiotherapy, and chronic irritation of the urachal remnant [1, 6, 8].

In the literature, xanthogranulomatous inflammation has been reported to occur in the age groups ranging from 23 to 72 years [6, 8]. However Tanwar et al. describe a case of xanthogranulomatous salpingo-oophoritis in a two-year-old girl who presented with an abdominal mass [4]. Presentation varies from abdominal to pelvic pain, fever, heavy menstrual bleeding, vaginal bleeding, and the findings of a pelvic mass [6, 8]. A case of xanthogranulomatous inflammation resulting in premature ovarian failure has also been described due to complete destruction of the ovarian tissue in the presence of an abdominal pelvic mass [10].

When xanthogranulomatous inflammation involves the endometrium, it can be associated with endometrial carcinoma [3, 10]. The cases of xanthogranulomatous endometritis, reported by Russack and Lammers, were all associated with endometrial carcinoma following radiotherapy with both external beam radiation and brachytherapy [11]. The mechanism proposed, which occurs uniquely in irradiated tissues, involves an interaction of inflammation, obstruction, a lipid source and generation of free radicals and lipid peroxidation [3].

In the fallopian tube, it is usually associated with pelvic inflammatory disease (PID) and endometriosis [10]. Xanthogranulomatous salpingitis is usually a unilateral phenomenon and can occur bilaterally [7]. The patient presents with a longstanding history of PID unresponsive to antibiotic treatment [7]. The organisms which have been implicated include *Escherichia coli*, *Pseudomonas aeruginosa*, *Bacteroides fragilis*, *Salmonella typhi*, *Proteus vulgaris*, *Staphylococcus aureus*, *Streptococcus viridans*, *Torulopsis (Candida) glabrata*, group B streptococci, and *Actinomyces* species [1, 4, 6].

Hysterosalpingography has also been implicated in the development of xanthogranulomatous salpingitis with lubricant jelly causing lipid accumulation and a granulomatous salpingitis [9].

In xanthogranulomatous salpingitis, a variable portion of the tube is thickened giving the appearance of a mass, as visualized in our case. Exudation is present on the serosal surface and there is usually obliteration of the fimbrial end; degeneration or necrosis is present on the edematous plicae and the latter is infiltrated by foam cells together with other chronic inflammatory cells [7].

In our case, endometriosis was implicated in the development of xanthogranulomatous salpingitis where sections from the left tube showed widespread endometriosis with glands and stroma together with the presence of numerous foam cells within the fallopian tube mucosa. This association with endometriosis is

indeed very rare and is not seen in the vast majority of young females with pelvic endometriosis [10]. It has been proposed that bleeding from endometriosis is important for the accumulation of the foamy macrophages. Altered blood and endometrial shedding from endometriosis could potentially lead to infections [1]. Our patient gave no history of previous pelvic infections. The persistence of the hemorrhagic ascites led to the diagnostic laparoscopy where the histological diagnosis of xanthogranulomatous salpingitis was made.

Endometriosis is rarely known to cause recurrent hemorrhagic ascites. Commoner causes of hemorrhagic ascites include a ruptured ectopic or hemorrhagic cyst, Meigs' syndrome, acute pancreatitis, or splenic rupture [12]. In our case, all of the above were excluded by means of the various imaging modalities described in the case presentation. It has been suggested that in endometriosis, the blood and endometrial cells which enter the peritoneal cavity cause an inflammatory reaction in the peritoneum resulting in hemorrhagic ascites [13].

It had been proposed by Furuya et al. that when xanthogranulomatous inflammation occurs on a background of endometriosis (as in our case) it should be referred to as pseudoxanthomatous salpingitis (PXS) while xanthogranulomatous changes arising from PID should be referred to as pure xanthogranulomatous salpingitis [14], the difference being that in PXS the histiocytes within the lamina propria are pigmented and contain the brown lipofuscin (ceroid) pigment [8, 15]. However, overlap exists between the two conditions, so certain authors classify both under xanthogranulomatous salpingitis [5].

It is thought that both lipid peroxidation of lysosomes and cellular components are responsible for the production of the lipofuscin pigment. The peroxidase theory and the proteolytic decline theory have a role in lipofuscin production [5]. The peroxidase theory involves the normal production of free oxygen radicals during metabolism which oxidizes fatty acids, the latter being stored in lysosomes which do not have the ability to remove these oxidized lipids. In addition, iron, zinc, and copper within the lysosomes catalyzes lipid peroxidation further [16]. On the other hand, the proteolytic decline theory occurs in normal ageing and suggests that lipofuscin precursors are handled less efficiently by lysosomes, this resulting in the deposition of lipofuscin with ageing cells [16].

CONCLUSION

The diagnosis of xanthogranulomatous inflammation is rare and remains a histological one, however it is important to know its relation to endometriosis. It inflammation is characterized by the replacement of the mucosa by granulation tissue with an infiltration of lipid-laden foamy macrophages together with an infiltrate of plasma cells, lymphocytes, neutrophils, eosinophils,

and multinucleated giant cells. Endometriosis should be considered in cases of hemorrhagic ascites once other causes are excluded.

REFERENCES

1. Abeysundara PK, Padumadasa GS, Tissera WG, Wijesinghe PS. Xanthogranulomatous salpingitis and oophoritis associated with endometriosis and uterine leiomyoma presenting as intestinal obstruction. *J Obstet Gynaecol Res* 2012;38(8):1115-7.
2. Yoshida A, Shirakuni A, Takeda A, Sugimoto M, Takeuchi K. Xanthogranulomatous inflammation of myometrium extended to the pelvis: Report of two cases. *Journal of Reproductive Immunology* 2016;118:125-6.
3. Narayan R, Mishra M, Mohanty R, Sinha TB. Xanthogranulomatous cervicitis. *Indian J Pathol Microbiol* 2008;51(3):458-9.
4. Tanwar H, Joshi A, Wagaskar V, Kini S, Bachhav M. Xanthogranulomatous salpingoophoritis: The youngest documented case report. *Case Rep Obstet Gynecol* 2015;2015:237250.
5. Idrees M, Zakashansky K, Kalir T. Xanthogranulomatous salpingitis associated with fallopian tube mucosal endometriosis: A clue to the pathogenesis. *Ann Diagn Pathol* 2007;11(2):117-21.
6. Gray Y, Libbey NP. Xanthogranulomatous salpingitis and oophoritis: A case report and review of the literature. *Arch Pathol Lab Med* 2001;125(2):260-3.
7. Zhang XS, Dong HY, Zhang LL, Desouki MM, Zhao C. Xanthogranulomatous inflammation of the female genital tract: Report of three cases. *J Cancer* 2012;3:100-6.
8. Howey JM, Mahe E, Radhi J. Xanthogranulomatous salpingitis associated with a large uterine leiomyoma. *Case Rep Med* 2010;2010:970805.
9. Chetty R, Reddy I, Batitang S. Xanthelasma or xanthoma of the fallopian tube. *Arch Pathol Lab Med* 2003;127(11):e417-9.
10. Singh N, Dadhwal V, Sharma KA, Mittal S. Xanthogranulomatous inflammation: A rare cause of premature ovarian failure. *Arch Gynecol Obstet* 2009;279(5):729-31.
11. Russack V, Lammers RJ. Xanthogranulomatous endometritis. Report of six cases and a proposed mechanism of development. *Arch Pathol Lab Med* 1990;114(9):929-32.
12. Hinduja I, Kapadia K, Udawadia F, Bhilawadikar R, Adhe A, Zaveri K. Unusual presentation of endometriosis with haemorrhagic ascites – A case report. *J Obstet Gynaecol* 2016;36(1):133-4.
13. Bernstein JS, Perlow V, Brenner JJ. Massive ascites due to endometriosis. *Am J Dig Dis* 1961;6:1-7.
14. Furuya M, Murakami T, Sato O, et al. Pseudoxanthomatous and xanthogranulomatous salpingitis of the fallopian tube: A report of four cases and a literature review. *Int J Gynecol Pathol* 2002;21(1):56-9.
15. Kostopoulou E, Daponte A, Kallitsaris A, et al. Xanthogranulomatous salpingitis: Report of three cases and comparison with a case of

pseudoxanthomatous salpingitis. *Clin Exp Obstet Gynecol* 2008;35(4):291-4.

16. Porta EA. Advances in age pigment research. *Arch Gerontol Geriatr* 1991;12(2-3):303-20.

Author Contributions

Marie Claire Vassallo – Conception of the work, Design of the work, Acquisition of data, Drafting the work, Revising the work critically for important intellectual content, Final approval of the version to be published, Agree to be accountable for all aspects of the work in ensuring that questions related to the accuracy or integrity of any part of the work are appropriately investigated and resolved

Mandy Collicot – Conception of the work, Design of the work, Revising the work critically for important intellectual content, Final approval of the version to be published, Agree to be accountable for all aspects of the work in ensuring that questions related to the accuracy or integrity of any part of the work are appropriately investigated and resolved

Kelvin Cortis – Design of the work, Revising the work critically for important intellectual content, Final approval of the version to be published, Agree to be accountable for all aspects of the work in ensuring that questions related to the accuracy or integrity of any part of the work are appropriately investigated and resolved

James DeGaetano – Conception of the work, Revising the work critically for important intellectual content, Final approval of the version to be published, Agree to be accountable for all aspects of the work in ensuring that questions related to the accuracy or integrity of any part of the work are appropriately investigated and resolved

Mark Formosa – Conception of the work, Revising the work critically for important intellectual content, Final approval of the version to be published, Agree to be accountable for all aspects of the work in ensuring that questions related to the accuracy or integrity of any part of the work are appropriately investigated and resolved

Guarantor of Submission

The corresponding author is the guarantor of submission.

Source of Support

None.

Consent Statement

Written informed consent was obtained from the patient for publication of this article.

Conflict of Interest

Authors declare no conflict of interest.

Data Availability

All relevant data are within the paper and its Supporting Information files.

Copyright

© 2019 Marie Claire Vassallo et al. This article is distributed under the terms of Creative Commons Attribution License which permits unrestricted use, distribution and reproduction in any medium provided

the original author(s) and original publisher are properly credited. Please see the copyright policy on the journal website for more information.

Access full text article on
other devices



Access PDF of article on
other devices





INTERNATIONAL JOURNAL OF
CASE REPORTS AND IMAGES



VIDEO JOURNAL OF
CLINICAL RESEARCH



VIDEO JOURNAL OF
BIOMEDICAL SCIENCE



INTERNATIONAL JOURNAL OF
HEPATOBIILIARY AND
PANCREATIC DISEASES



INTERNATIONAL JOURNAL OF
BLOOD TRANSFUSION AND
IMMUNOHEMATOLOGY



EDORIUM JOURNAL OF
OPHTHALMOLOGY



Submit your manuscripts at
www.edoriumjournals.com



EDORIUM JOURNAL OF
MEDICINE



EDORIUM JOURNAL OF
CARDIOTHORACIC AND
VASCULAR SURGERY



JOURNAL OF CASE REPORTS
AND IMAGES IN ORTHOPEDICS
AND RHEUMATOLOGY



EDORIUM JOURNAL OF
PSYCHOLOGY



EDORIUM JOURNAL OF
CELL BIOLOGY



JOURNAL OF CASE REPORTS AND IMAGES IN
DENTISTRY



EDORIUM JOURNAL OF
CANCER



EDORIUM JOURNAL OF
PSYCHIATRY



JOURNAL OF CASE REPORTS AND
IMAGES IN INFECTIOUS DISEASES



EDORIUM JOURNAL OF
ANATOMY AND EMBRYOLOGY



EDORIUM JOURNAL OF
SURGERY



JOURNAL OF CASE REPORTS
AND IMAGES IN PATHOLOGY



EDORIUM JOURNAL OF
ANESTHESIA