

CASE REPORT

PEER REVIEWED | OPEN ACCESS

A finding of subcutaneous emphysema: Diagnosing and managing Hamman's syndrome in a postpartum patient

Joseph W Bacchi, GERALYN O'REILLY

ABSTRACT

Introduction: Hamman's syndrome, first described by Dr. Louis Hamman in 1945, is a medical condition that results in subcutaneous emphysema secondary to rupture of weakened alveoli. Although it was first described 73 years ago, the disorder is not widely known among obstetricians. This case report discusses the diagnosis and management of Hamman's syndrome. **Case Report:** A 27-year-old, otherwise healthy nulliparous woman presented to the hospital in active labor. She underwent an uncomplicated vaginal delivery. On postpartum day one she presented with crepitus, hoarseness, and facial swelling. Imaging revealed subcutaneous emphysema and pneumopericardium. The patient received a cardiothoracic surgery consult, was ruled out for esophageal rupture, and monitored overnight. Symptoms resolved spontaneously and the patient was followed up as an outpatient. **Conclusion:** Clinical manifestations of Hamman's syndrome can vary widely, making the diagnosis difficult. Providers must be aware of the risk factors and manifestations of the disorder for proper diagnosis and management. Hamman's syndrome is typically a self-limiting disorder that will resolve spontaneously, however, it is important to rule out severe differential diagnoses.

Joseph W Bacchi¹, GERALYN O'REILLY²

Affiliations: ¹Resident Physician, Sinai Hospital of Baltimore, Department of Obstetrics and Gynecology, Baltimore, Maryland, USA; ²Attending Physician, Sinai Hospital of Baltimore, Department of Maternal Fetal Medicine, Baltimore, Maryland, USA.

Corresponding Author: Joseph W Bacchi, 212 Washington Avenue, Apartment 416, Towson, Maryland 21204, USA; Email: jbacchi@lifebridgehealth.org

Received: 08 May 2019

Accepted: 24 June 2019

Published: 09 August 2019

Keywords: Hamman's syndrome, Postpartum, Subcutaneous emphysema

How to cite this article

Bacchi JW, O'Reilly G. A finding of subcutaneous emphysema: Diagnosing and managing Hamman's syndrome in a postpartum patient. J Case Rep Images Obstet Gynecol 2019;5:100052Z08JB2019.

Article ID: 100052Z08JB2019

doi:10.5348/100052Z08JB2019CR

INTRODUCTION

Hamman's syndrome is the term used to describe pneumomediastinum, or air within the central compartment of the thoracic cavity. It is a condition that was first described by Dr. Louis Hamman who first noted the findings of pneumomediastinum in association with subcutaneous emphysema during pregnancy in 1945 [1]. The disorder can occur in the second stage of labor with strong Valsalva maneuvers, but may not be detected until the postpartum period. Hamman's syndrome is caused by barotrauma that results in rupture of alveolar membranes causing a positive pressure gradient of air from the lungs to the mediastinum and subcutaneous tissues [2]. Symptoms can range from being asymptomatic to having dyspnea, dysphonia, chest pain, and low grade fevers. It can be diagnosed clinically however imaging studies may help. As part of the diagnosis it is essential to rule out more severe causes of pneumomediastinum, such as pneumothorax and esophageal perforation. Its treatment course is largely supportive as Hamman's syndrome is a self-limiting condition [2]. We discuss a case in which the initial diagnosis of Hamman's syndrome was detected by the patient in the early postpartum period.

CASE REPORT

We present a case of a 27-year-old gravida one para zero who presented to labor and delivery at 40 weeks with a complaint of contractions. Her vital signs were within normal limits. She was found to be 6 cm dilated, 80% effaced, 0 station; the cervix was soft and anterior. Her Bishop score was 12. Membranes were intact and the fetus was in the vertex presentation. The fetal heart tracing was category 1 and she was contracting every two minutes. The patient was expectantly managed. She underwent spontaneous rupture of membranes and subsequently underwent a spontaneous vaginal delivery to a female infant weighing 3620 grams with Apgar scores of 9 at one minute and 9 at five minutes. The second stage of labor was routine and lasting under three hours. The vaginal delivery was associated with a blood loss of 300 ml and a second degree perineal laceration that was repaired with 2-0 chromic suture.

This pregnancy was only complicated by being Rh negative. The patient received Rho (D) immunoglobulin at 28 weeks gestation and again on postpartum day one. Her prenatal labs were otherwise normal. She had no significant medical or surgical history and only an allergy to sulfa drugs. She does not use alcohol, tobacco, or illicit drugs.

On postpartum day one the patient noticed facial swelling, hoarseness of voice, and a crackling sensation underneath her skin on her chest and neck extending up to her ears. Being that our patient was a nurse, she correctly identified it as crepitus. Her vital signs were within normal limits and postpartum labs were appropriate. On exam there was palpable crepitus in the posterior auricular area as well as in the cervical region of the neck and upper chest. There were no carotid bruits and her lungs were clear to auscultation. There was however a loud three component friction rub at the left lower sternal border and apex. A pericardial friction rub may be a sign of pericarditis [3].

The patient underwent a chest X-ray that revealed diffuse subcutaneous emphysema throughout the entire neck (as indicated by the arrow heads). The emphysema extended inferiorly to the mediastinum and pericardial space (as indicated by the star). It extended superiorly to the base of the skull and laterally to the supraclavicular regions and left axilla. There was no evidence of a pneumothorax (Figure 1). An electrocardiogram (EKG) was also performed and found to have a normal sinus rhythm.

The patient was transferred to our hospital for a higher level of care for concerns of possible esophageal perforation. Upon arrival the patient was hemodynamically stable. She had no pulmonary or cardiac concerns. There was no clinical concern of esophageal perforation. She had no respiratory complaints and no issues with swallowing or speaking; she denied any throat pain. She was seen by both, the obstetric and thoracic surgery teams. The patient was

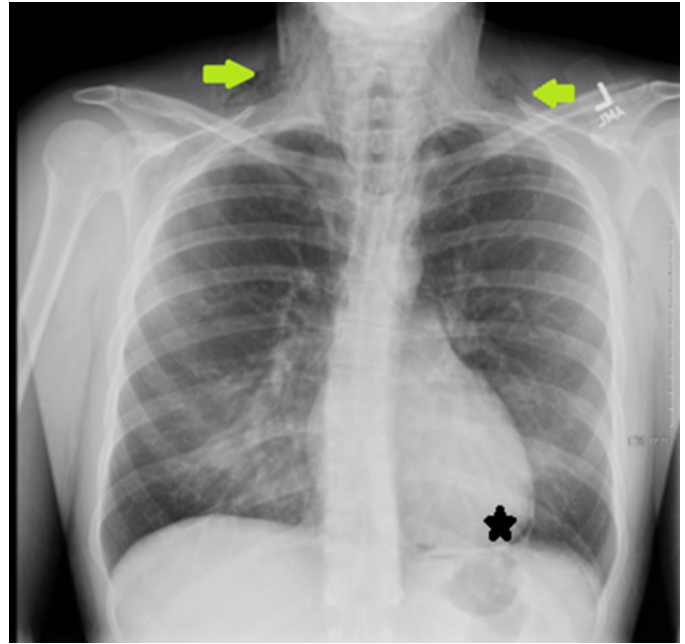


Figure 1: Chest X-ray showing subcutaneous emphysema (arrows) and pneumopericardium (star).

stable and kept for observation overnight. She was then discharged on postpartum day three with conservative management.

The patient was sent for an outpatient chest X-ray on postpartum day nine. At that time the subcutaneous and pericardial emphysema had resolved. The patient also stated that symptoms had improved. She was seen by her private obstetrician for her six week postpartum follow-up. At that time there was no residual findings from her episode of Hamman's syndrome.

DISCUSSION

Hamman's syndrome, or spontaneous pneumomediastinum (air within the central compartment of the thoracic cavity), is a rare clinical disorder that is not well known to many physicians. It was first described by Dr. Louis Hamman in 1945 in an obstetric patient with subcutaneous emphysema after having increased Valsalva effort during the second stage of labor. Although it has been observed in obstetric and postpartum patients, this disorder can be seen in other populations. In fact, 70% of cases are seen in young men.

Hamman's syndrome has a documented incidence of 1:44,000 in the general population and 1:100,000 in obstetric patients [1, 4]. Majority of cases of Hamman's syndrome occur between the ages of 5 and 34. Although typically seen in young, healthy individuals, some risk factors for the disorder include asthma, Chronic Obstructive Pulmonary Disease (COPD), interstitial pulmonary diseases, tobacco use, and continuous drug inhalation. Hamman's syndrome is often preceded by vomiting, coughing, upper respiratory infections, labor,

constipation, drug use, physical exercise, and balloon inflating or instrument playing [4].

The pathogenesis behind the disorder is that increased intrathoracic pressure causes weakened alveolar membranes to rupture. A positive pressure gradient exists and air is passively spread from the lungs to the mediastinum along perivascular connective tissue. It then spreads superiorly into visceral, retropharyngeal, and subcutaneous tissue of the chest and neck [2]. Pneumomediastinum is associated with subcutaneous emphysema or pneumothorax in 40–100% of cases of Hamman's syndrome [5]. Hamman's syndrome is typically a benign disorder that can be conservatively managed with observation. Clinical symptoms can vary from being asymptomatic to having dyspnea and chest pain. A classical finding referred to as Hamman's sign consists of precordial crunching sounds synchronous with a heartbeat and is only present in one half of all cases of Hamman's syndrome [5].

Often times the diagnosis of Hamman's syndrome can be made clinically however a chest X-ray and computed tomography (CT) scan may be helpful to rule out a pneumothorax or esophageal perforation. An EKG is also an important tool as a small percentage of patients may have EKGs with low voltage, T wave inversion, or nonspecific ST segment changes [2]. Hamman's syndrome overall has a good prognosis. There are only four reported cases of maternal fatality, all of which were recorded prior to 1908 [6]. Due to the lack of available records, it is plausible that the diagnosis of Hamman's syndrome at that time was an incorrect diagnosis as the differential diagnosis includes disorders that are more life threatening. The differential diagnosis for a patient with subcutaneous emphysema includes Hamman's syndrome, pneumothorax, esophageal perforation, and pericarditis.

The treatment is largely supportive as symptoms will usually resolve spontaneously within 3–14 days [6]. There is no evidence to support future diagnostic, treatment, or preventative measures. The risk of recurrence in future pregnancies is rare although some may argue for epidural analgesia, operative (vacuum/forceps) delivery, and avoidance of nitrous oxide in future pregnancies as nitrous oxide can increase intra-alveolar pressure [6]. There is limited evidence to support these suggestions.

CONCLUSION

Hamman's syndrome is typically a self-limiting disorder that can occur during the second stage of labor. Although it is a benign disorder, it is important to identify and diagnose the disorder appropriately and rule out other, more severe medical diagnoses. Hamman's syndrome is well documented in other parts of the world; however, case reports in the United States

are limited. This article aids in provider education on the clinical manifestations, diagnosis, and management of intrapartum or postpartum Hamman's syndrome.

REFERENCES

1. Majer S, Graber P. Postpartum pneumomediastinum (Hamman's syndrome). *CMAJ* 2007;177(1):32.
2. Cho C, Parratt JR, Smith S, Patel R. Spontaneous pneumomediastinum (Hamman's syndrome): A rare cause of postpartum chest pain. *BMJ Case Rep* 2015;2015. pii: bcr1220103603.
3. Phelan D, Collier P, Grimm RA. *Pericardial Disease*. Cleveland Clinic 2015.
4. Grapatsas K, Tsilogianni Z, Leivaditis V, et al. Hamman's syndrome (spontaneous pneumomediastinum presenting as subcutaneous emphysema): A rare case of the emergency department and review of the literature. *Respir Med Case Rep* 2017;23:63–5.
5. Unlu M, Cimen P, Oner E. An unusual cause of cough: Hamman's syndrome. *Int J Sci Stud* 2015;3(6):214–6.
6. Kuruba N, Hla T. Postpartum spontaneous pneumomediastinum and subcutaneous emphysema: Hamman's syndrome. *Obstet Med* 2011;4(3):127–8.

Acknowledgments

A special thank you to the patient for agreeing to participate in this case report as well as the faculty and staff at Sinai Hospital of Baltimore.

Author Contributions

Joseph W Bacchi – Design of the work, Acquisition of data, Analysis of data, Interpretation of data, Drafting the work, Final approval of the version to be published, Agree to be accountable for all aspects of the work in ensuring that questions related to the accuracy or integrity of any part of the work are appropriately investigated and resolved

Geralyn O'Reilly – Conception of the work, Design of the work, Revising the work critically for important intellectual content, Final approval of the version to be published, Agree to be accountable for all aspects of the work in ensuring that questions related to the accuracy or integrity of any part of the work are appropriately investigated and resolved

Guarantor of Submission

The corresponding author is the guarantor of submission.

Source of Support

None.

Conflict of Interest

Authors declare no conflict of interest.

Data Availability

All relevant data are within the paper and its Supporting Information files.

Copyright

© 2019 Joseph W Bacchi et al. This article is distributed under the terms of Creative Commons Attribution


License which permits unrestricted use, distribution and reproduction in any medium provided the original author(s) and original publisher are properly credited. Please see the copyright policy on the journal website for more information.

Access full text article on
other devices



Access PDF of article on
other devices





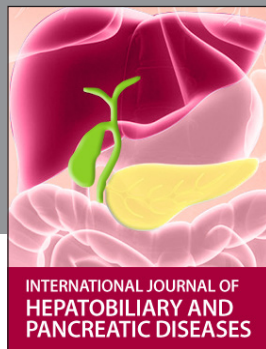INTERNATIONAL JOURNAL OF
CASE REPORTS AND IMAGES



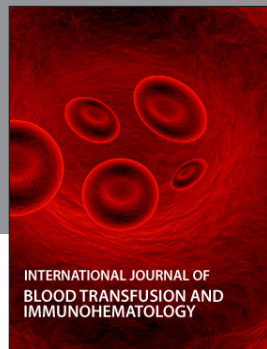VIDEO JOURNAL OF
CLINICAL RESEARCH



VIDEO JOURNAL OF
BIOMEDICAL SCIENCE




INTERNATIONAL JOURNAL OF
HEPATOBIILIARY AND
PANCREATIC DISEASES



INTERNATIONAL JOURNAL OF
BLOOD TRANSFUSION AND
IMMUNOHEMATOLOGY



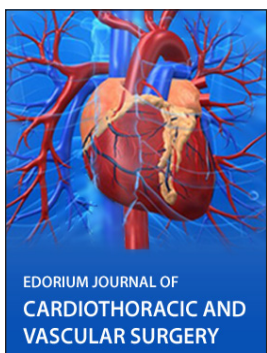EDORIUM JOURNAL OF
OPHTHALMOLOGY



Submit your manuscripts at
www.edoriumjournals.com



EDORIUM JOURNAL OF
MEDICINE



EDORIUM JOURNAL OF
CARDIOTHORACIC AND
VASCULAR SURGERY



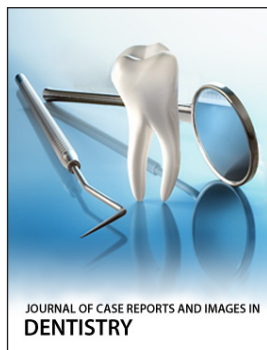
JOURNAL OF CASE REPORTS
AND IMAGES IN ORTHOPEDICS
AND RHEUMATOLOGY



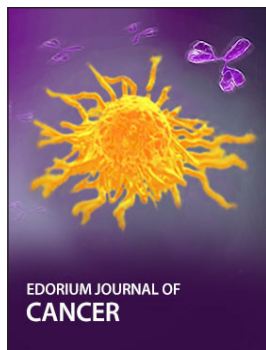EDORIUM JOURNAL OF
PSYCHOLOGY




EDORIUM JOURNAL OF
CELL BIOLOGY



JOURNAL OF CASE REPORTS AND IMAGES IN
DENTISTRY



EDORIUM JOURNAL OF
CANCER



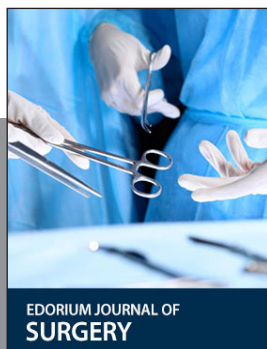EDORIUM JOURNAL OF
PSYCHIATRY



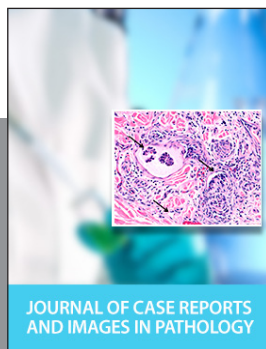JOURNAL OF CASE REPORTS AND
IMAGES IN INFECTIOUS DISEASES



EDORIUM JOURNAL OF
ANATOMY AND EMBRYOLOGY



EDORIUM JOURNAL OF
SURGERY



JOURNAL OF CASE REPORTS
AND IMAGES IN PATHOLOGY



EDORIUM JOURNAL OF
ANESTHESIA