

Case of postpartum eclampsia in a patient with isolated proteinuria

Hala Hassan, Hicham Zaarour, Nadim Hajal, Rana Skaf,
Jihad Al Hassan, Manal Zaarour

ABSTRACT

Introduction: Eclampsia is traditionally defined as the occurrence of seizures in pregnant women, usually in the setting of preeclampsia and in the absence of other neurologic disorders. It is mostly a peripartum pathology occurring mainly before, during, or within 48 hours after delivery. When convulsions occur in the postpartum phase, the diagnosis becomes more challenging and worthy of comprehensive investigations. **Case Report:** Our case is an atypical presentation of eclampsia occurring in the postpartum period in a patient with no previous symptomatology related to preeclampsia except for isolated proteinuria. **Conclusion:** This presentation of eclampsia leads to the conclusion that an atypical occurrence of this disease is becoming more frequent, and thus raises the concern towards the burden this can have on the associated maternal and neonatal morbidity and mortality.

Hala Hassan¹, Hicham Zaarour², Nadim Hajal³, Rana Skaf⁴,
Jihad Al Hassan⁵, Manal Zaarour⁶

Affiliations: ¹Senior Resident, Department of Obstetrics and Gynecology at St George Hospital University Medical Center, Beirut, Lebanon; ²Senior Resident, Department of Obstetrics and Gynecology at Al Zahraa University Hospital, Beirut, Lebanon; ³MFM Specialist, Department of Obstetrics and Gynecology at St George Hospital University Medical Center, Beirut, Lebanon; ⁴Chief of Department, Department of Obstetrics and Gynecology at St George Hospital University Medical Center, Beirut, Lebanon; ⁵Chief of Department, Department of Obstetrics and Gynecology at Al Zahraa University Hospital, Beirut, Lebanon; ⁶Obstetrics and Gynecology Specialist, Department of Obstetrics and Gynecology at Al Zahraa University Hospital, Beirut, Lebanon.

Corresponding Author: Hala Hassan, St George Hospital University Medical Center, Ashrafyeh, Beirut, Lebanon; Email: Halahassan9989@gmail.com

Received: 22 August 2019

Accepted: 17 September 2019

Published: 18 October 2019

Keywords: Eclampsia, Encephalopathy, Hypertension, Preeclampsia

How to cite this article

Hassan H, Zaarour H, Hajal N, Skaf R, Al Hassan J, Zaarour M. Case of postpartum eclampsia in a patient with isolated proteinuria. J Case Rep Images Obstet Gynecol 2019;5:100053Z08HH2019.

Article ID: 100053Z08HH2019

doi: 10.5348/100053Z08HH2019CR

INTRODUCTION

Traditionally preeclampsia has been defined as a disorder of pregnancy characterized by hypertension and proteinuria of ≥ 300 mg/day. It is a serious disorder which may lead to maternal and fetal morbidity and mortality [1]. In general, most women will have a classic presentation of preeclampsia (hypertension and proteinuria) at >20 weeks of gestation and/or <48 hours after delivery [2].

Eclampsia is defined by new-onset tonic-clonic, focal, or multifocal seizures in the absence of other causative conditions, such as epilepsy, cerebral arterial ischemia and infarction, intracranial hemorrhage, or drug use [3]. The entity called "late onset postpartum eclampsia" is defined by its onset more than 48 hours after delivery which differentiates it from "early postpartum eclampsia" that occurs in the window of 48 hours following delivery [4].

Eclampsia remains as a major obstetric complication that inflicts a large percentage of maternal and perinatal morbidities. In general, most women will have a classical presentation of preeclampsia. However, studies and case reports have suggested that some women will develop eclampsia without the classical findings. We are

presenting a case of early onset (<48 hours) postpartum eclampsia in a patient with isolated proteinuria and no prior history of kidney disease or chronic hypertension.

CASE REPORT

This is the case of an 18-year-old female patient primigravid through a spontaneous pregnancy with a dichorionic diamniotic gestation at 32 weeks and 5 days admitted to the hospital for management of preterm labor.

The patient had an unremarkable medical or surgical history. She denied any allergies to food or medication. Her sole medications were prenatal vitamins and Rovamycin for toxoplasmosis first trimester seroconversion. She denied alcohol and illicit drug use.

On admission, the patient had a cervical dilation of 2 centimeters (cm) and an effacement of 70% with no fluid leakage or vaginal bleeding. She had regular contractions every 4 minutes and a nonstress test showed reassuring category I fetal heart rates. The patient was afebrile with a heart rate (HR) of 82 beats per minute (bpm) and a blood pressure (BP) of 110/70 mmHg.

Labs on admission showed the following: hemoglobin of 10.5 g/dL, hematocrit of 33.5%, platelet count of 429,000/ μ L, white blood cells of 12,200/ μ L, normal prothrombin time and international normalized ratio (PT INR) and activated partial thromboplastin time (aPTT), a urine analysis was negative except for trace proteins, and C-reactive protein (CRP) was negative (2.11 mg/L). Vaginal and urine cultures came out negative as well.

The patient was admitted for tocolysis view the preterm labor and so was put on Tractocile (Atosiban) protocol [a loading dose of 6.75 mg in 0.9 L normal saline (NS) followed by a maintenance dose of 37.5 mg in 0.9 L NS infused at a rate of 8 mL/h] to which she directly responded. She was given a full course of steroids [Dexamethasone 6 mg intramuscular (IM) every 12 hours for four doses] over two days. Magnesium sulfate was given for neural protection (4 g intravenous over 30 minutes).

An obstetrical ultrasound done on admission day 1 showed a dichorionic diamniotic gestation with normal placentation and no signs of previa, fetus A = fetus 1, female, vertex, estimated fetal weight (EFW) = 1576 g (20th percentile), fetus B = 2, female, breech, EFW = 1879 g (40th percentile), adequate amniotic fluid around both fetuses and normal umbilical artery Doppler.

On day 9 of admission, a urine analysis, part of full routine lab work up, showed 3+ protein which raised alertness for possible preeclamptic signs. To note that throughout her admission, the patient had documented BP readings below 120 mmHg for systolic blood pressure (SBP) and 80 mmHg for diastolic blood pressure (DBP) as per nursing charts. The patient denied any symptoms of preeclampsia (headache and epigastric pain) and any history of past hypertensive episodes.

Hence, a preeclampsia work-up was ordered and was normal except for proteinuria. Urine analysis showed 2+ proteins. Twenty-four hour urine collection showed a value of 943 mg/24 hour. Blood pressure was monitored closely and readings did not exceed 120/80 mmHg. Patient had no complaints except for her irregular contractions with no prodromes of preeclampsia. A kidney ultrasound was done as well and was normal (a minimal left hydronephrosis was noted).

The patient was kept in hospital for close observation and monitoring in between repeat courses of tocolysis due to recurrence of preterm contractions upon completion of each Atosiban protocol. On day 14 of admission and after four repeated courses, tocolysis was stopped and the patient was delivered by cesarean section at 34 weeks and 5 days.

The cesarean delivery went uneventful with delivery of two live baby girls APGAR score of 9/10, baby A vertex, weight = 1.9 kilograms (kg) and baby B breech, weight = 2 kg, both transferred to the Neonatal Intensive Care Unit (NICU) for grunting and retractions. The patient was stable throughout the cesarean delivery and the following postoperative period (BP was maintained at 120/60 mmHg throughout the operation and the estimated blood loss was 300 mL). She was transferred to the maternity floor with regular postpartum care including pain management, antibiotics, and anticoagulation therapy. Vital signs: HR = 82 bpm, oxygen saturation $\text{SaO}_2 = 98\%$, temperature $T = 36.4^\circ\text{C}$, BP = 130/90 mmHg. The patient was awake, alert, and oriented.

On the night of day 0 postpartum, the patient developed suddenly a full blown tonic-clonic seizure (duration about around 3 minutes) with loss of consciousness and biting of the tongue followed by a postictal phase (confusion, no loss of stools, urinary loss could not be assessed since the patient had a Foley catheter postcesarean section) with slow return of consciousness. Magnesium sulfate (MgSO_4) loading dose (4 g) was directly given after the seizure, however, the patient developed a second tonic-clonic episode of seizure. Magnesium sulfate maintenance dose was started directly after loading dose which coincided with the second seizure. Vital signs taken directly after the consecutive episodes of seizure: HR = 90, $\text{SaO}_2 = 98\%$, $T = 37^\circ\text{C}$, BP = 150/90 mmHg.

A full blood work-up as well as arterial blood gas (ABG) was taken. Results came out as follows: uric acid 6.9, creatinine 0.82, normal liver enzymes, normal PT INR and aPTT. A complete blood count showed: hemoglobin 12.4 g/dL, hematocrit 36.9%, platelet count 389,000/ μ L. Arterial blood gas results showed metabolic acidemia which was normalized after 2 hours.

The patient was transferred to the intensive care unit (ICU) for close monitoring. To note, she regained full consciousness after the second episode of seizure and was stable clinically with a urine output of 50 cc/h (adequate to patient weight), her BP was at 140/90 mmHg during transfer.

The patient was kept in the ICU with continuous MgSO₄ infusion for three days with daily lab work-up that kept being normal except for a uric acid level reaching a maximum of 7.5 mg/dL on day 1 of ICU admission. Mg level was closely monitored and kept within the therapeutic level. The patient's BP was stabilized with an average of 130/80 mmHg with Aldomet (Methyldopa) 500 mg per os (PO) three times daily. She did not suffer from any further seizures. The neurological exam was normal. A brain computed tomography (CT) scan without contrast showed the following: presence of hypodense regions at the cortex and subcortex of the temporal and occipital lobes. This aspect correlates with vasogenic edema related to preeclampsia and with posterior reversible encephalopathy syndrome (PRES).

The patient and family refused to proceed with a magnetic resonance imaging (MRI) as recommended for further evaluation. An electroencephalogram (EEG) was however ordered and showed slowing of delta and theta waves that were attributed to the seizure episodes with no signs of epilepsy.

The patient was still stable and got transferred to the regular maternity floor for three days where she got regular postpartum care and close BP monitoring. MgSO₄ was stopped on day 5 postseizure. The patient was now clinically and hemodynamically stable with BP readings <140/80 mmHg, adequate urine output (around 40 cc/h), and normal cognition. She was discharged on day 6 postoperatively against medical advice.

The patient was followed as outpatient afterward and her seizures did not recur.

DISCUSSION

Eclampsia is a rare but serious obstetric complication. It accounts for 12% of maternal deaths worldwide despite its rare incidence of 1.6–10 cases per 10,000 deliveries. The onset of eclampsia can occur antepartum, intrapartum, or postpartum. Most antenatal and intrapartum cases present to obstetricians, however, postpartum cases are more likely to present to the emergency department (ED) and hence the majority is managed by nonobstetricians with delay in diagnosis and management. In the postpartum period, the onset of convulsions has been reported within the first 48 hours as well as beyond 48 hours (late postpartum period) [5, 6]. In the literature focused on recent decades, it has been noted that the pattern of eclampsia has changed. Interestingly, Chames et al. in 2002 found that one-third of the cases of eclampsia in the years 1996–2001 have developed after delivery, with 79% developing beyond 48 hours postpartum [7].

Aside from its onset, what interests us is the atypical presentation of eclampsia traditionally known to be preceded with well-identified prodromal signs and symptoms. These include headache, visual changes, hypertension, epigastric discomfort, and proteinuria,

and are present in up to four-fifths of subsequently eclamptic patients [8]. In fact, it has become essential to acknowledge the nonclassical and atypical features of preeclampsia and eclampsia and their respective management to prevent the costly consequence of a missed diagnosis and its eventual possible fatalities [9].

Our case represents one of the rare documented cases in the literature describing late postpartum eclamptic patients with an unconventional presentation. Veltkamp et al. reported the occurrence of eclampsia in two patients starting nine days postpartum. Headache and visual disturbances preceded the seizures but none of the classic preeclamptic signs were present until shortly before seizure onset [10]. Also, in 2009, Ginzburg et al. reported a case of a patient presenting on postpartum day 5 to the ED with a one-day history of a gradual-onset throbbing occipital headache that was associated with photophobia and three episodes of vomiting. Her BP on presentation was 205/105 mmHg [11].

In 2015, Garg et al. reported the case of a 28-year-old woman presenting to the ED with a chief complaint of headache of four days duration, eight days after an uncomplicated, normal vaginal delivery. Her past medical history was unremarkable and her entire pregnancy was without medical incident. The patient's examination was within normal limits other than a BP of 152/111 mmHg and pulse of 54 bpm and later developed a tonic-clonic seizure in the ED [12]. This case is also an example of postpartum eclampsia presenting to health care givers other than obstetricians and promoting the necessity of a multidisciplinary alertness to this disease especially in the first week postpartum [13].

Posterior reversible encephalopathy syndrome encompasses a variety of acute neurologic symptoms such as seizure, impaired consciousness, and visual disturbances in a background of reversible vasogenic brain edema commonly involving the bilateral parieto-occipital regions. Recent studies have noted that PRES is becoming an essential component of eclampsia-mediated primary central nervous system injury. In a recent study published in 2016, Mayama et al. stated that 92.3% of patients with eclampsia and neurologic symptoms showed radiological evidence of PRES [14].

In a case report published by Munjuluri et al. in 2005, a postpartum patient who only had isolated proteinuria starting her 30th week of gestation suffered an eclamptic seizure with evidence of PRES, however, she had a hypertensive episode reaching 200/112 mmHg [15].

Our case is an example of early postpartum eclampsia (within <48 hours postpartum). The convulsions were associated with neuroimaging compatible with PRES after exclusion of other possible etiologies of seizure in the setting of a postpartum patient with history of isolated proteinuria during the third trimester.

This case is unique for multiple reasons. First, our patient was normotensive and did not show any predictive signs or symptoms typically directing

toward preeclampsia and eclampsia; the onset of her convulsions was sudden in a context of a normal early postpartum course. Second, she ended up developing eclamptic seizures with neurologic imaging suggestive of PRES which is usually a consequence of significant hypertension-related endothelial damage [16].

CONCLUSION

Our case raises a real concern for atypical presentations of eclampsia, especially in the postpartum period. In fact, this entails the necessity for close monitoring of gravid women with any sign of preeclampsia and systematic recommendations to these patients to seek medical care by their obstetricians upon onset of any alarming symptom in the postpartum period. To be vigilant, the one week after discharge appears to be the critical period for the development of postpartum eclampsia and thus education about the possibility of delayed postpartum preeclampsia and eclampsia should occur after delivery even if patients do not develop hypertensive disease before discharge from the hospital.

REFERENCES

1. El-Sayed AAF. Preeclampsia: A review of the pathogenesis and possible management strategies based on its pathophysiological derangements. *Taiwan J Obstet Gynecol* 2017;56(5):593–8.
2. Sibai BM, Stella CL. Diagnosis and management of atypical preeclampsia-eclampsia. *Am J Obstet Gynecol* 2009;200(5):481.e1–7.
3. ACOG practice bulletin no. 202: Gestational Hypertension and Preeclampsia. *Obstet Gynecol* 2019;133(1):e1–25.
4. Minnerup J, Kleffner I, Wersching H, et al. Late onset postpartum eclampsia: It is really never too late—A case of eclampsia 8 weeks after delivery. *Stroke Res Treat* 2010;2010. pii: 798616.
5. Niroomanesh S, Mirzaie F. Atypical postpartum eclampsia: Status epilepticus without preeclamptic prodromi. *Women Birth* 2008;21(4):171–3.
6. Hirshfeld-Cytron J, Lam C, Karumanchi SA, Lindheimer M. Late postpartum eclampsia: Examples and review. *Obstet Gynecol Surv* 2006;61(7):471–80.
7. Chames MC, Livingston JC, Ivester TS, Barton JR, Sibai BM. Late postpartum eclampsia: A preventable disease? *Am J Obstet Gynecol* 2002;186(6):1174–7.
8. Kane SC, Dennis A, da Silva Costa F, Kornman L, Brennecke S. Contemporary clinical management of the cerebral complications of preeclampsia. *Obstet Gynecol Int* 2013;2013:985606.
9. Stella CL, Sibai BM. Preeclampsia: Diagnosis and management of the atypical presentation. *J Matern Fetal Neonatal Med* 2006;19(7):381–6.
10. Veltkamp R, Kupsch A, Polasek J, Yousry TA, Pfister HW. Late onset postpartum eclampsia without preeclamptic prodromi: Clinical and neuroradiological presentation in two patients. *J Neurol Neurosurg Psychiatry* 2000;69(6):824–7.

11. Ginzburg VE, Wolff B. Headache and seizure on postpartum day 5: Late postpartum eclampsia. *CMAJ* 2009;180(4):425–8.
12. Garg D, Rahaman B, Stein EG, Dickman E. Late postpartum eclampsia with postpartum angiopathy: An uncommon diagnosis in the emergency department. *J Emerg Med* 2015;49(6):e187–91.
13. Al-Safi Z, Imudia AN, Filetti LC, Hobson DT, Bahado-Singh RO, Awonuga AO. Delayed postpartum preeclampsia and eclampsia: Demographics, clinical course, and complications. *Obstet Gynecol* 2011;118(5):1102–7.
14. Mayama M, Uno K, Tano S, Yoshihara M, Ukai M, Kishigami Y, Ito Y, Oguchi H. Incidence of posterior reversible encephalopathy syndrome in eclamptic and patients with preeclampsia with neurologic symptoms. *Am J Obstet Gynecol* 2016;215(2):239.e1–5.
15. Munjuluri N, Lipman M, Valentine A, Hardiman P, Maclean AB. Postpartum eclampsia of late onset. *BMJ* 2005;331(7524):1070–1.
16. Camara-Lemarroy CR, Escobedo-Zúñiga N, Villarreal-Garza E, Garcia-Valadez E, Góngora-Rivera F, Villarreal-Velázquez HJ. Posterior reversible leukoencephalopathy syndrome (PRES) associated with severe eclampsia: Clinical and biochemical features. *Pregnancy Hypertens* 2017;7:44–9.

Author Contributions

Hala Hassan – Conception of the work, Design of the work, Acquisition of data, Revising the work critically for important intellectual content, Final approval of the version to be published, Agree to be accountable for all aspects of the work in ensuring that questions related to the accuracy or integrity of any part of the work are appropriately investigated and resolved

Hicham Zaarour – Conception of the work, Design of the work, Acquisition of data, Revising the work critically for important intellectual content, Final approval of the version to be published, Agree to be accountable for all aspects of the work in ensuring that questions related to the accuracy or integrity of any part of the work are appropriately investigated and resolved

Nadim Hajal – Conception of the work, Design of the work, Acquisition of data, Revising the work critically for important intellectual content, Final approval of the version to be published, Agree to be accountable for all aspects of the work in ensuring that questions related to the accuracy or integrity of any part of the work are appropriately investigated and resolved

Rana Skaf – Conception of the work, Design of the work, Acquisition of data, Revising the work critically for important intellectual content, Final approval of the version to be published, Agree to be accountable for all aspects of the work in ensuring that questions related to the accuracy or integrity of any part of the work are appropriately investigated and resolved

Jihad Al Hassan – Conception of the work, Design of the work, Acquisition of data, Revising the work critically for important intellectual content, Final approval of the version to be published, Agree to be accountable for all aspects of the work in ensuring that questions related to the accuracy or integrity of any part of the work are appropriately investigated and resolved

Manal Zaarour – Conception of the work, Design of the work, Acquisition of data, Revising the work critically for important intellectual content, Final approval of the version to be published, Agree to be accountable for all aspects of the work in ensuring that questions related to the accuracy or integrity of any part of the work are appropriately investigated and resolved

Guarantor of Submission

The corresponding author is the guarantor of submission.

Source of Support

None.

Consent Statement

Written informed consent was obtained from the patient for publication of this article.

Conflict of Interest

Authors declare no conflict of interest.

Data Availability

All relevant data are within the paper and its Supporting Information files.

Copyright

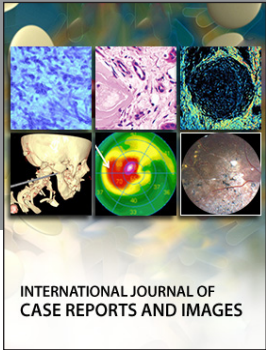
© 2019 Hala Hassan et al. This article is distributed under the terms of Creative Commons Attribution License which permits unrestricted use, distribution and reproduction in any medium provided the original author(s) and original publisher are properly credited. Please see the copyright policy on the journal website for more information.

Access full text article on
other devices



Access PDF of article on
other devices





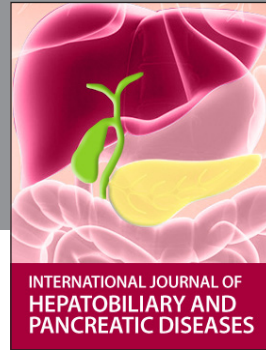INTERNATIONAL JOURNAL OF CASE REPORTS AND IMAGES



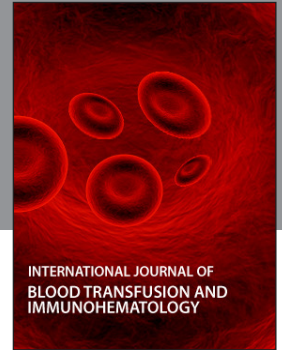VIDEO JOURNAL OF CLINICAL RESEARCH



VIDEO JOURNAL OF BIOMEDICAL SCIENCE



INTERNATIONAL JOURNAL OF HEPATOBILIARY AND PANCREATIC DISEASES



INTERNATIONAL JOURNAL OF BLOOD TRANSFUSION AND IMMUNOHEMATOLOGY



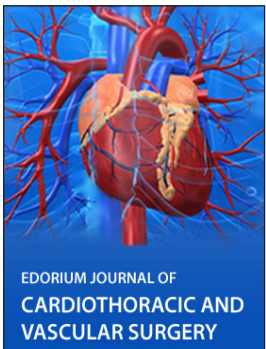
EDORIUM JOURNAL OF OPHTHALMOLOGY



Submit your manuscripts at
www.edoriumjournals.com



EDORIUM JOURNAL OF MEDICINE



EDORIUM JOURNAL OF CARDIOTHORACIC AND VASCULAR SURGERY



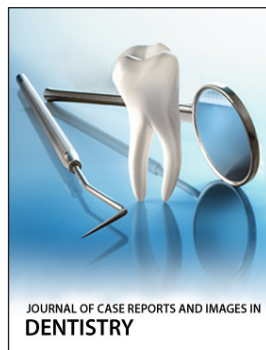
JOURNAL OF CASE REPORTS AND IMAGES IN ORTHOPEDICS AND RHEUMATOLOGY



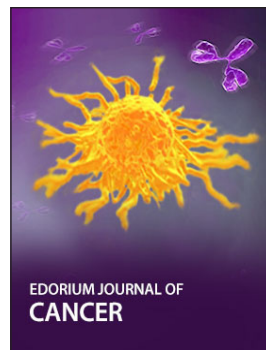EDORIUM JOURNAL OF PSYCHOLOGY




EDORIUM JOURNAL OF CELL BIOLOGY



JOURNAL OF CASE REPORTS AND IMAGES IN DENTISTRY



EDORIUM JOURNAL OF CANCER



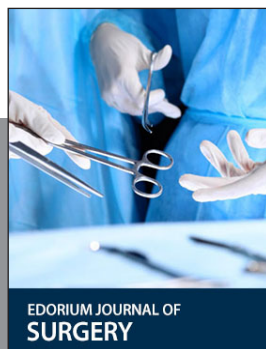EDORIUM JOURNAL OF PSYCHIATRY



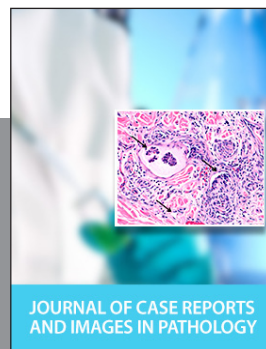JOURNAL OF CASE REPORTS AND IMAGES IN INFECTIOUS DISEASES



EDORIUM JOURNAL OF ANATOMY AND EMBRYOLOGY



EDORIUM JOURNAL OF SURGERY



JOURNAL OF CASE REPORTS AND IMAGES IN PATHOLOGY



EDORIUM JOURNAL OF ANESTHESIA