

# Uterine septum as a risk factor for placenta accreta in primigravid woman

Meagan Slate, Caroline Shell

## ABSTRACT

**Introduction:** Morbidly adherent placenta is a rare obstetrical complication associated with significant maternal morbidity. Known risk factors include a history of cesarean section, uterine instrumentation, placenta previa, and multiparity. Congenital uterine anomalies may be an additional risk factor for abnormal placentation. **Case Report:** A 28-year-old, healthy, primigravid woman presented status post-vaginal delivery, complicated by retained placenta requiring manual extraction, dilation and curettage (D&C), and blood transfusion. Subsequent imaging revealed a persistently retained placenta with loss of the myometrial/endometrial border, diagnostic of placenta accreta. The patient underwent bilateral uterine artery embolization for conservative management of placenta accreta, and subsequent hysteroscopy revealed a significant uterine septum. **Conclusion:** Uterine anomalies may increase a patient's risk of abnormal placentation. Persistently retained placenta after initial D&C warrants detailed imaging [i.e., magnetic resonance imaging (MRI)] to rule out abnormally adherent placenta.

**Keywords:** Placenta accreta, Primigravid, Uterine anomalies

## How to cite this article

Slate M, Shell C. Uterine septum as a risk factor for placenta accreta in primigravid woman. J Case Rep Images Obstet Gynecol 2019;5:100055Z08MS2019.

Article ID: 100055Z08MS2019

\*\*\*\*\*

doi: 10.5348/100055Z08MS2019CR

## INTRODUCTION

Placenta accreta, defined as abnormal invasion of placental villi into the uterine myometrium, is a potentially devastating obstetric complication and can result in massive postpartum hemorrhage. With mortality rates as high as 7% in some studies, it is important to diagnose the condition before delivery and attempted removal of the placenta [1]. Traditional risk factors for placenta accreta include placenta previa, prior cesarean delivery, prior uterine instrumentation, multiparity, and advanced maternal age [2]. It has been proposed that congenital uterine anomalies may also contribute to abnormal placentation; however, only a limited number of cases have been reported [3–5].

The gold standard treatment for placenta accreta has traditionally been Cesarean hysterectomy. However, numerous reports can be found in the literature of successful use of conservative treatment that allows for avoidance of hysterectomy and preservation of future fertility in up to 80% of cases [6]. The optimal approach to conservative management of placenta accreta remains an active area of investigation, and therapies include uterine devascularization and/or medical therapy with methotrexate. It is well documented in the literature that Müllerian anomalies are associated with increased risk of miscarriage, intrauterine growth restriction (IUGR), and preterm birth. Rarely has it been suggested that Müllerian anomalies are associated with abnormal placentation, and no case reports have linked uterine septa to placenta

Meagan Slate<sup>1</sup>, Caroline Shell<sup>2</sup>

**Affiliations:** <sup>1</sup>Resident (PGY4), Department of OBGYN, Sinai Hospital of Baltimore, Baltimore, Maryland, USA; <sup>2</sup>Attending, Department of OBGYN, Sinai Hospital of Baltimore, Baltimore, Maryland, USA.

**Corresponding Author:** Meagan Slate, 2401 W Belvedere Ave, Baltimore, Maryland 21215, USA; Email: Meagan-slate@gmail.com

Received: 24 June 2019

Accepted: 22 October 2019

Published: 15 November 2019

accreta. Here we present a case of a primigravid woman who was diagnosed with placenta accreta in the absence of known risk factors and, after conservative management, was subsequently found to have a uterine septum.

## CASE REPORT

A healthy 28-year-old primigravid woman with a singleton pregnancy underwent an induction of labor at an affiliated institution, for cholestasis of pregnancy with elevated bile acids at 37 weeks gestation. Her starting hemoglobin (Hb) was 13.8 g/dL. She had a vaginal delivery complicated by a retained placenta. After one hour of expectant management, manual removal of the placenta was performed. The patient was known to have a posterior placenta based on prior ultrasounds; however, no placental abnormalities were identified prior to delivery. The patient recovered well and was discharged home on postpartum day #2. She returned to the hospital the same evening with complaints of palpitations, fever, chills, shortness of breath, and pelvic pain. She reported significant vaginal bleeding, and her Hb level was 9.5. At the time of admission, she was tachycardic, tachypneic, and febrile to 39.4°C. A transvaginal ultrasound showed a diffusely thickened, heterogeneous endometrium, measuring 4.6 cm, consistent with retained products of conception, as well as echogenic areas suggestive of air concerning for endometritis. The patient was started on Gentamicin and Clindamycin.

She underwent a suction D&C the following morning. The pathology report read “markedly necrotic, hemorrhagic tissue with chorionic villi consistent with retained products of conception.” The procedure was complicated by intraoperative hemorrhage, requiring transfusion of two units of packed red blood cells for a Hb of 7.3. Several hours later, the patient remained febrile and appeared septic with a leukocytosis of 18,600/mm<sup>3</sup> and an elevated lactate (3.5 mmol/L). Due to concerns for worsening clinical status, ampicillin plus sulbactam was added to the patient’s antibiotic regimen.

The patient’s clinical picture gradually improved on hospital days #3 and #4 with normalization of her lactate, and resolution of her fever. Her white blood cell (WBC) count remained elevated at 18,000/mm<sup>3</sup>. A repeat transvaginal ultrasound was performed, which showed “retained products of conception, unchanged from her prior ultrasound.” At this point, the patient was transferred to our institution for further care. She continued to have abdominal pain and a moderate amount of bright red vaginal bleeding; however, her vital signs had normalized and she was no longer febrile.

Given the patient’s history of persistently retained products of conception after a suction D&C, pelvic MRI was obtained to investigate the possibility of abnormal placentation, despite the patient’s lack of risk factors. The T2-weighted MRI revealed loss of the hyperintense endometrial line at the endometrial–myometrial

interface, posteriorly in the uterine corpus and fundus. In addition, an area highly concerning for myometrial invasion of the retained products, in conjunction with the patient’s clinical picture, confirmed the diagnosis of placenta accreta. There was no evidence of placental percreta or invasion of the adjacent posterior structures. She was also noted to have duplication of the left ureter.

Treatment options were reviewed with the patient and her husband. They strongly desired conservative management with uterine artery embolization to preserve future fertility. Interventional radiology performed bilateral uterine artery embolization through the right common femoral artery using Gelfoam. Following the procedure, the patient’s vaginal bleeding slowed significantly. She was discharged home the following day in stable condition.

Over several weeks, the patient’s vaginal bleeding slowed to light pink spotting. Her human chorionic gonadotropin (hCG) levels trended to zero and remained undetectable. Six months postpartum, the patient complained of cramping and mild spotting. A transvaginal ultrasound showed a subcentimeter calcified lesion within the endometrial cavity, concerning for retained products of conception (Figure 1).

The patient was again counseled on her options, and she elected to undergo operative hysteroscopy with D&C to remove the remaining tissue.

During the hysteroscopy, a large, midline, intrauterine septum was noted to occupy the entire endometrial cavity. These findings were not reported on any previous imaging. Left cornual synechiae and a calcified lesion on the posterior wall of the uterus were also discovered. The TruClear® (Medtronic, USA) operative hysteroscope was used to carefully dissect the uterine septum until bilateral tubal ostia could be appreciated. The synechiae and posterior uterine lesion were removed until the uterine cavity was restored to normal contours. Though previous imaging did not report evidence of an anomalous uterus, we remained cautious throughout the case to avoid uterine perforation. The patient had minimal bleeding and was discharged home. The final pathology showed only scant fragments of benign endometrial tissue with no evidence of chorionic villi or decidua.

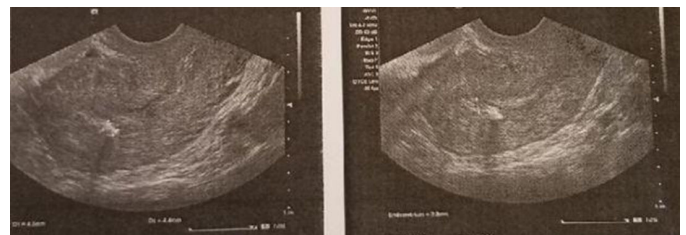


Figure 1: Transvaginal ultrasound imaging six months after bilateral uterine artery embolization for conservative management of placenta accreta. Findings significant for a subcentimeter calcified lesion within the endometrial cavity, concerning for retained products of conception.

## DISCUSSION

Placenta accreta, defined as abnormal invasion of placental villi into the uterine myometrium, is a potentially devastating obstetric complication whose incidence is unfortunately rising. Often, it is first suspected due to abnormal findings on obstetric ultrasound in the asymptomatic patient. These abnormal findings include multiple large, irregular placental lacunae, or the classic “moth eaten” appearance which usually have turbulent internal flow [7]. The lacunae are more linear, rather than rounded, and they do not have the highly echogenic border that standard venous sinuses have. Bleeding may be the first symptom if a patient has a placenta previa, however the first clinical manifestation is usually profuse, life-threatening hemorrhage that occurs with attempted manual placental separation. Part or all of the placenta remains strongly attached to the uterine cavity, and no plane of separation can be developed [8].

Clinically significant risk factors for placenta accreta include placenta previa, prior cesarean delivery, prior uterine instrumentation, multiparity, and advanced maternal age [2]. There are case reports of patients with uterine anomalies whose pregnancies were complicated by placenta accreta, suggesting that abnormal placentation can contribute to adverse outcomes. Only a limited number of cases have been reported describing uterine anomalies and abnormal placentation, one of which described an abnormally adherent placenta with a uterine didelphys at 18 weeks [3]. Another article examined 85 women with uterine anomalies and reported that 3 women were diagnosed with placenta accreta (4.5%), noting that the frequency of placenta accreta is much higher than the general obstetric population (0.09–0.17%) [5].

It is important to highlight the utility of imaging, specifically MRI, to rule out placenta accreta in the setting of delayed postpartum hemorrhage. Magnetic resonance imaging is indicated in the diagnostic workup when the ultrasound evaluation is equivocal or for patients with high clinical risk factors for placenta accreta. In cases where ultrasound has already made a definitive diagnosis, MRI is often used to plan the cesarean section delivery and peripartum hysterectomy [9]. In this case report, manual extraction of the placenta was first attempted, followed by a suction D&C, yet the patient was still noted to have retained products of conception several days after the procedure. In this setting, a placenta accreta must be ruled out. It is reasonable to suggest that patients with delayed postpartum hemorrhage, specifically 48 hours after delivery, warrant a workup to rule out morbidly adherent placenta.

The unique aspects of this case include a rare obstetrical complication lacking the traditional risk factors for placenta accreta, successful conservative management of placenta accreta, and delayed hysteroscopic findings of a septate uterus.

Important topics of discussion include the conservative management of placenta accreta, and how it

was successfully applied in this case. While the patient's uterus remains in situ, she did require broad-spectrum antibiotics in the setting of sepsis, multiple blood transfusions, and additional surgical procedures (D&C ×2, uterine artery embolization), in order to maintain her fertility. The effects of these interventions are not yet known.

## CONCLUSION

Placenta accreta is known to be a potential life threatening condition, and early diagnosis can aid in preparation for cesarean hysterectomy and assembly of blood products. Although major risk factors for abnormal placentation have been well published in the literature, placenta accreta has occurred in young, nulliparous patients without a history of intrauterine instrumentation, and the pathophysiology of this complication is not always understood. Uterine anomalies should be considered a risk factor for abnormal placentation in an otherwise uncomplicated patient, especially in the setting of persistently retained products of conception. There are only a few cases in the literature to suggest congenital uterine anomalies as a risk factor for placenta accreta; however, these cases involved uterine didelphys and unicornuate uterus. This is the first case report to suggest uterine septum as a risk factor for placenta accreta.

## REFERENCES

1. O'Brien JM, Barton JR, Donaldson ES. The management of placenta percreta: Conservative and operative strategies. *Am J Obstet Gynecol* 1996;175(6):1632–8.
2. Gielchinsky Y, Rojansky N, Fasouliotis SJ, Ezra Y. Placenta accreta—summary of 10 years: A survey of 310 cases. *Placenta* 2002;23(2–3):210–4.
3. Tuştaş Haberal E, Çekmez Y, Ulu İ, Divlek R, Göçmen A. Placenta percreta with concomitant uterine didelphys at 18 weeks of pregnancy: A case report and review of the literature. *J Matern Fetal Neonatal Med* 2016;29(21):3445–8.
4. Kaplanoğlu M. The uterine sandwich method for placenta previa accreta in mullerian anomaly: Combining the B-lynch compression suture and an intrauterine gauze tampon. *Case Rep Obstet Gynecol* 2013;2013:236069.
5. Lekovich J, Stewart J, Anderson S, Niemasik E, Pereira N, Chasen S. Placental malperfusion as a possible mechanism of preterm birth in patients with Müllerian anomalies. *J Perinat Med* 2017;45(1):45–9.
6. Bretelle F, Courbière B, Mazouni C, et al. Management of placenta accreta: Morbidity and outcome. *Eur J Obstet Gynecol Reprod Biol* 2007;133(1):34–9.
7. Pagni G, Cali G, Acharya G, et al. Diagnostic accuracy of ultrasound in detecting the severity of abnormally invasive placentation: A systematic review and meta-analysis. *Acta Obstet Gynecol Scand* 2018;97(1):25–37.

8. Lax A, Prince MR, Mennitt KW, Schwebach JR, Budorick NE. The value of specific MRI features in the evaluation of suspected placental invasion. *Magn Reson Imaging* 2007;25(1):87–93.
9. Kilcoyne A, Shenoy-Bhangle AS, Roberts DJ, Sisodia RC, Gervais DA, Lee SI. MRI of placenta accreta, placenta increta, and placenta percreta: Pearls and pitfalls. *AJR Am J Roentgenol* 2017;208(1):214–21.

\*\*\*\*\*

### Acknowledgments

A special thank you to the patient for agreeing to participate in this case report, as well as the faculty at Sinai Hospital of Baltimore.

### Author Contributions

Meagan Slate – Conception of the work, Design of the work, Acquisition of data, Analysis of data, Interpretation of data, Drafting the work, Revising the work critically for important intellectual content, Final approval of the version to be published, Agree to be accountable for all aspects of the work in ensuring that questions related to the accuracy or integrity of any part of the work are appropriately investigated and resolved

Caroline Shell – Conception of the work, Design of the work, Acquisition of data, Analysis of data, Interpretation of data, Drafting the work, Revising the work critically for important intellectual content, Final approval of the version to be published, Agree to be accountable for all

aspects of the work in ensuring that questions related to the accuracy or integrity of any part of the work are appropriately investigated and resolved

### Guarantor of Submission

The corresponding author is the guarantor of submission.

### Source of Support

None.

### Consent Statement

Written informed consent was obtained from the patient for publication of this article.

### Conflict of Interest

Authors declare no conflict of interest.

### Data Availability

All relevant data are within the paper and its Supporting Information files.

### Copyright

© 2019 Meagan Slate et al. This article is distributed under the terms of Creative Commons Attribution License which permits unrestricted use, distribution and reproduction in any medium provided the original author(s) and original publisher are properly credited. Please see the copyright policy on the journal website for more information.

Access full text article on  
other devices



Access PDF of article on  
other devices





INTERNATIONAL JOURNAL OF  
CASE REPORTS AND IMAGES



VIDEO JOURNAL OF  
CLINICAL RESEARCH



VIDEO JOURNAL OF  
BIOMEDICAL SCIENCE



INTERNATIONAL JOURNAL OF  
HEPATOBIILIARY AND  
PANCREATIC DISEASES



INTERNATIONAL JOURNAL OF  
BLOOD TRANSFUSION AND  
IMMUNOHEMATOLOGY



EDORIUM JOURNAL OF  
OPHTHALMOLOGY



**Submit your manuscripts at**  
[www.edoriumjournals.com](http://www.edoriumjournals.com)



EDORIUM JOURNAL OF  
MEDICINE



EDORIUM JOURNAL OF  
CARDIOTHORACIC AND  
VASCULAR SURGERY



JOURNAL OF CASE REPORTS  
AND IMAGES IN ORTHOPEDICS  
AND RHEUMATOLOGY



EDORIUM JOURNAL OF  
PSYCHOLOGY



EDORIUM JOURNAL OF  
CELL BIOLOGY



JOURNAL OF CASE REPORTS AND IMAGES IN  
DENTISTRY



EDORIUM JOURNAL OF  
CANCER



EDORIUM JOURNAL OF  
PSYCHIATRY



JOURNAL OF CASE REPORTS AND  
IMAGES IN INFECTIOUS DISEASES



EDORIUM JOURNAL OF  
ANATOMY AND EMBRYOLOGY



EDORIUM JOURNAL OF  
SURGERY



JOURNAL OF CASE REPORTS  
AND IMAGES IN PATHOLOGY



EDORIUM JOURNAL OF  
ANESTHESIA