

CASE REPORT

PEER REVIEWED | OPEN ACCESS

Term delivery following spontaneous resolution of uterine arteriovenous malformation with subsequent in vitro fertilization

Brooke Malia Fenske, Jennifer Marie Burgart, Meaghan Shanahan

ABSTRACT

Introduction: A uterine arteriovenous malformation (AVM) is an abnormal connection between the arterial and venous systems and is clinically relevant due to the risk of hemorrhage and death. Arteriovenous malformations are often treated with uterine artery embolization which may compromise fertility. Conservative management is one treatment option that can preserve fertility; however, limited data has documented fertility success after conservative management, especially in the context of later pregnancy achieved by in vitro fertilization (IVF). This case report presents a successful case of IVF after spontaneous resolution of a uterine AVM. **Case Report:** A 40-year-old G1P0100 Caucasian female presented to a six-week postpartum visit with episodic vaginal bleeding after spontaneous vaginal delivery of a previable infant in the setting of preterm premature rupture of membranes complicated by chorioamnionitis. Transvaginal ultrasound (TVUS) and pelvic magnetic resonance imaging (MRI) were consistent with

a uterine AVM. Due to the desire for fertility preservation, the patient elected for conservative management, and spontaneous resolution of the lesion was seen on TVUS six weeks later. Successful pregnancy was later achieved with IVF and resulted in delivery of a healthy term infant. **Conclusion:** Conservative management is a viable treatment option for hemodynamically stable patients with uterine AVMs who desire future fertility. In this case, this abnormality did not preclude the patient from becoming pregnant and having a successful obstetric outcome. While risks do exist with conservative management, ultimately the treatment of patients with uterine AVMs must be individualized, and the clinical picture must be balanced with the wishes of the patient.

Keywords: In vitro fertilization, Pregnancy, Uterine arteriovenous malformation

How to cite this article

Fenske BM, Burgart JM, Shanahan M. Term delivery following spontaneous resolution of uterine arteriovenous malformation with subsequent in vitro fertilization. J Case Rep Images Obstet Gynecol 2020;6:100056Z08BF2020.

Article ID: 100056Z08BF2020

doi:10.5348/100056Z08BF2020CR

Brooke Malia Fenske¹, Jennifer Marie Burgart², Meaghan Shanahan³

Affiliations: ¹BS, Medical Student, Department of Obstetrics and Gynecology, Creighton University, Omaha, Nebraska, USA; ²MD, MS, Resident Physician, PGY-III, Department of Obstetrics and Gynecology, Creighton University, Omaha, Nebraska, USA; ³MD, FACOG, Residency Program Director and Assistant Professor, Department of Obstetrics and Gynecology, Creighton University, Omaha, Nebraska, USA.

Corresponding Author: Meaghan Shanahan, MD, FACOG, Program Director and Assistant Professor, Department of Obstetrics and Gynecology, Creighton University, School of Medicine, Omaha, Nebraska, USA; Email: MeaghanShanahan@Creighton.edu

Received: 09 September 2019

Accepted: 21 November 2019

Published: 23 January 2020

INTRODUCTION

A uterine arteriovenous malformation (AVM) is the result of an abnormal connection between the venous and arterial systems and is generally of congenital or acquired

etiology. Acquired AVMs are commonly a result of uterine trauma, including gynecologic procedures, cesarean sections, dilation and curettage, intrauterine infections, and gestational trophoblastic disease [1–3]. However, uterine AVMs have also been documented in women without a history of trauma following an uncomplicated pregnancy [4].

While uterine AVMs are rare, multiple case reports have documented findings of this condition. The most common presenting symptom is vaginal bleeding, but patients may also remain asymptomatic [4]. Uterine AVMs are of clinical importance as this abnormality can lead to excessive hemorrhage and even death. Recent research has also provided diagnostic guidance by emphasizing the utility of specific color Doppler ultrasound findings in uterine AVMs [5]. While ultrasound is commonly the initial test of choice, magnetic resonance imaging (MRI), computed tomography, and angiography can also be used to make or support the diagnosis [6].

There are several methods available for treatment of uterine AVMs, but conservative management is one strategy that can provide fertility preservation and time for potential resolution of the abnormality. However, limited longitudinal data has been documented investigating fertility success after conservative management and malformation resolution, especially in the context of pregnancy achieved by in vitro fertilization (IVF). This case report documents a case of spontaneous resolution of a uterine AVM followed by successful pregnancy achieved by IVF.

CASE REPORT

A 40-year-old G1P0100 Caucasian female presented to clinic with reported frequent, episodic heavy vaginal bleeding and cramping at a postpartum visit. She denied fevers, chills, or other associated symptoms. Physical exam was within normal limits. Hemoglobin was 12.5 g/dL and human chorionic gonadotropin level was negative. Six weeks earlier, she had delivered a preivable infant at 21 weeks, 3 days gestation after preterm premature rupture of membranes (PPROM) at 21 weeks 0 day gestation, subsequently complicated by chorioamnionitis. This necessitated labor induction with vaginal misoprostol in addition to ampicillin and gentamicin. She then had an otherwise uncomplicated vaginal delivery with spontaneous delivery of the placenta. The placenta appeared intact on inspection and was sent for evaluation by pathology and found to be significant for grade 3 chorioamnionitis. She was discharged from the hospital on postpartum day one with no medical complaints and only minimal lochia. Pregnancy had been conceived via intrauterine insemination (IUI) secondary to the patient being in a same-sex relationship and was only complicated by a large episode of vaginal bleeding at 8 weeks, 2 days gestation, for which the patient was assessed in the Emergency Department for threatened abortion. Of note,

there were no significant ultrasound findings other than a viable intrauterine pregnancy documented in records of that visit. Noninvasive prenatal testing done during early pregnancy showed no abnormalities. Past medical history was significant for prediabetes, depression, anxiety, left bundle branch block, asthma, hypothyroidism, gastric reflux disease, heterozygous MTHFR gene mutation, chronic hypertension, migraines, polycystic ovarian syndrome, obstructive sleep apnea, attention deficit disorder, asymptomatic premature ventricular complexes, class III obesity [body mass index (BMI) 45], and Rh negativity. Daily medications included: metformin, duloxetine, prenatal vitamins, folic acid, aspirin 81 mg, and use of a continuous positive airway pressure machine during sleep. Gynecologic history was significant for menarche at age 13 with 30–32 day menstrual cycles and a remote history of an abnormal pap test with positive human papillomavirus and subsequent normal pap tests since. Past surgical history was notable for a hysteroscopic uterine polypectomy two years prior with normal hysterosalpingogram at that time. Patient denied tobacco, alcohol, or drug use.

A TVUS with Doppler was performed, showing large prominent vessels coursing in the anterior myometrium to endometrial canal with flow (Figure 1). The differential diagnosis included retained products of conception (POC) versus possible placenta accreta versus subinvolution of placental site versus uterine AVM. Pelvic MRI was also completed and showed findings consistent with possible retained POC with a potential increta component versus uterine AVM (Figure 2). However, after further conference with a maternal fetal medicine specialist and a second radiologist, the final diagnosis of uterine AVM was confirmed. After discussion of treatment options with the patient including uterine arterial embolization (UAE), she elected for conservative management due to her stable condition and her preference for fertility preservation.

The patient desired to become pregnant again and followed with her reproductive endocrinology and infertility (REI) specialist. A follow-up TVUS with saline infusion sonohysterography (SIS) six weeks later was negative for any pathology or signs of the previous uterine AVM per review of the REI records. With presumed spontaneous resolution of the uterine AVM, the patient underwent a repeat IUI which resulted in a spontaneous abortion. Due to the failed IUI attempt, the patient then underwent IVF and achieved a successful pregnancy. A prophylactic cerclage at 14 weeks gestation and hydroxyprogesterone caproate supplementation were used throughout the pregnancy due to history of PPRM. Interestingly, early ultrasounds in pregnancy did show dilated vessels in the anterior myometrium at 11 weeks, 6 days gestation (Figure 3) which were again present, but smaller in size at 22 weeks, 6 days gestation (Figure 4). The patient remained totally asymptomatic throughout pregnancy with no abnormal bleeding episodes. As a result of poor glucose control and preeclampsia without severe features, she was delivered at 37 weeks gestation.

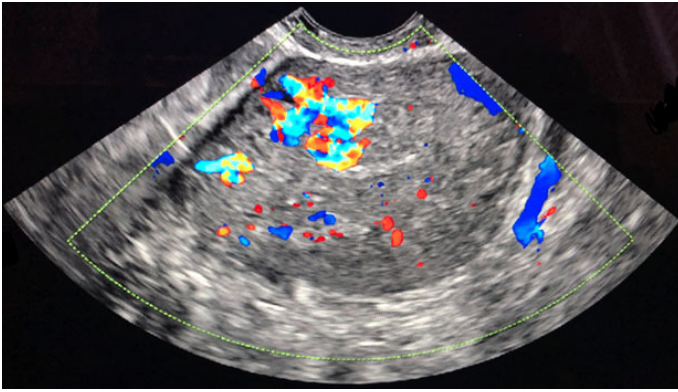


Figure 1: TVUS transverse view of uterine AVM demonstrating increased blood flow in anterior myometrium.

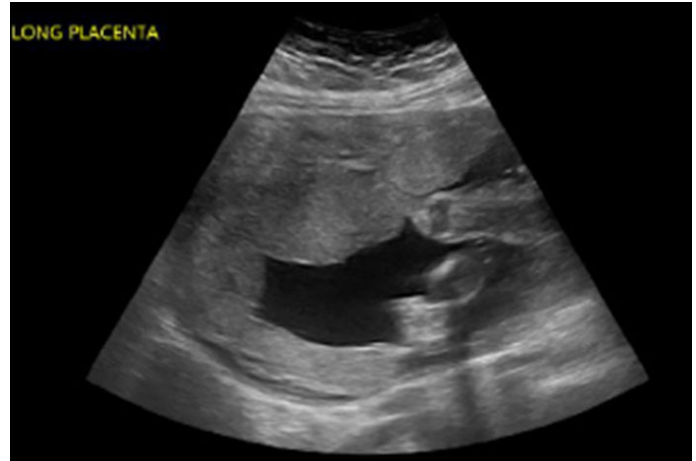


Figure 4: Ultrasound at 22w6d of IVF pregnancy demonstrating smaller, dilated vessels in anterior myometrium.

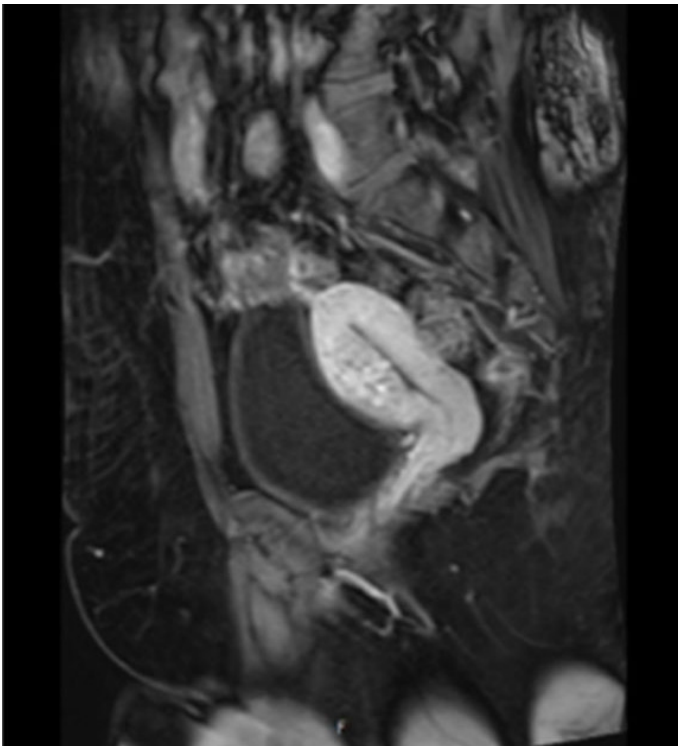


Figure 2: Pelvic MRI of uterine AVM showing abnormal vessels in anterior myometrium.

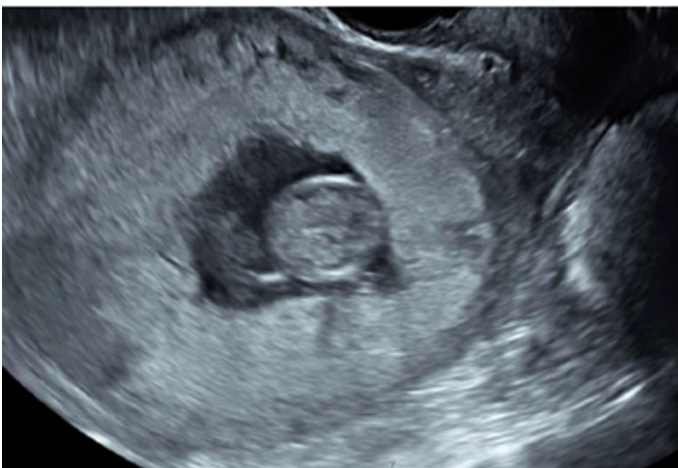

Figure 3: Ultrasound at 11w6d of IVF pregnancy demonstrating small, dilated vessels in anterior myometrium.

The method of delivery was via primary low transverse cesarean section due to fetal breech presentation, and she delivered a healthy infant with no complications. Estimated blood loss at time of delivery was 1000 mL and no abnormalities were appreciated on gross inspection of the uterus. She then had an uncomplicated postpartum course and had resumed a normal menstrual period at her 6 week postpartum visit. A TVUS at 5 weeks and again at 10 months postpartum did not show any abnormalities or residual vessel dilation.

DISCUSSION

Historically, treatment for symptomatic uterine AVMs generally included hysterectomy or, in the case of desired future fertility, UAE. More recent case reports have also focused on various medical management strategies and even conservative treatment, as some uterine AVMs have been shown to resolve without intervention [7–9]. While UAE is the most popular treatment of choice for symptomatic patients who desire future fertility, this procedure has provided mixed outcomes, and may even pose potential risks for placental abnormalities and other pregnancy complications [6, 10–13]. With these limitations in mind, it is essential to consider conservative management as a realistic and practical mode of treatment for a uterine AVM. One clear benefit of conservative management is the preservation of fertility for women who desire future childbearing; however, limited longitudinal data has been collected in this group of women and their subsequent obstetric outcomes, as most of the current literature focuses on fertility after UAE [4, 6, 10]. Some studies have followed pregnancy after diagnosis of a uterine AVM but fail to examine pregnancy rates specifically in the conservative management group [4]. Additionally, several case reports have documented spontaneous resolution of uterine AVMs, but the majority of studies lack follow-up regarding future pregnancies or associated complications [8, 9]. Although a few case reports have provided fertility data after untreated

uterine AVM resolution, these cases have not examined pregnancy achieved by IVF specifically [14, 15].

Many studies have investigated the risk factors associated with failed IVF attempts, especially in relation to obesity. Preconception BMI has been shown to affect IVF success, where women with Class II/III obesity have higher rates of IVF cycle cancellation, fewer oocytes and embryos, and lower pregnancy rates overall [16]. Furthermore, preconception obesity is associated with an increased risk of pregnancy complications including spontaneous abortions, intrauterine fetal demise, hypertensive disorders of pregnancy, gestational diabetes, congenital anomalies, and delivery by cesarean section [17]. While preconception obesity has been identified as a risk factor for failed IVF, the role of a current or prior uterine AVM in terms of fertility success remains unknown. As assisted reproductive treatments are a common method of achieving pregnancy, study findings must be applicable to this growing body of women.

While conservative management of uterine AVMs offers several benefits to patients, it also presents its own set of risks, including the potential for life-threatening hemorrhage. Sudden rupture of the uterine AVM can occur, necessitating emergent UAE or even hysterectomy [15, 18]. Such hemodynamic instability could result in catastrophic outcomes, including potential loss of future fertility or even death, which may have been avoided with earlier UAE or alternative intervention. Due to the risk of hemorrhage, prophylactic measures should be taken at the time of delivery in patients with a current or prior uterine AVM. Available resources should include a patient blood type and screen, units of blood on hold for immediate use, postpartum hemorrhage medications in the room, and available interventional radiology staff for UAE and surgical team for cesarean hysterectomy if an emergent situation occurred. Unfortunately, it is impossible to predict if or when a uterine AVM may rupture, thus each patient must be properly informed of all potential outcomes and allowed to make an educated and individualized decision with their physician.

CONCLUSION

Uterine AVMs should always be considered in the differential of a patient presenting with episodic heavy vaginal bleeding, especially in the setting of past uterine trauma, manipulation, or pregnancy. Conservative management is a viable treatment option for hemodynamically stable women with uterine AVMs who desire future fertility. In this case, having a history of this abnormality did not preclude our patient from becoming pregnant again and delivering a healthy infant at term. While risks do exist with conservative management, ultimately the treatment of any woman with a uterine AVM must be individualized and chosen with the full clinical picture as well as wishes of the patient in mind.

REFERENCES

1. Corusic A, Barisic D, Lovric H, Despot A, Plainic P. Successful laparoscopic bipolar coagulation of a large arteriovenous malformation due to invasive trophoblastic disease: A case report. *J Minim Invasive Gynecol* 2009;16(3):368–71.
2. Kim D, Moon NR, Lee SR, et al. Acquired uterine arteriovenous malformation in a cesarean scar pregnancy. *Taiwan J Obstet Gynecol* 2013;52(4):590–2.
3. Rygh AB, Greve OJ, Fjetland L, Berland JM, Eggebø TM. Arteriovenous malformation as a consequence of a scar pregnancy. *Acta Obstet Gynecol Scand* 2009;88(7):853–5.
4. Eling R, Kent A, Robertson M. Pregnancy after uterine arteriovenous malformation-case series and literature review. *Australas J Ultrasound Med* 2012;15(3):87–96.
5. Lee TY, Kim SH, Lee HJ, et al. Ultrasonographic indications for conservative treatment in pregnancy-related uterine arteriovenous malformations. *Acta Radiol* 2014;55(9):1145–52.
6. Grivell RM, Reid KM, Mellor A. Uterine arteriovenous malformations: A review of the current literature. *Obstet Gynecol Surv* 2005;60(11):761–7.
7. Nonaka T, Yahata T, Kashima K, Tanaka K. Resolution of uterine arteriovenous malformation and successful pregnancy after treatment with a gonadotropin-releasing hormone agonist. *Obstet Gynecol* 2011;117(2 Pt 2):452–5.
8. Ghizzoni V, Gabbrielli S, Mannini L, et al. Spontaneous resolution of an acquired uterine arteriovenous malformation in an elderly primigravida. *Am J Case Rep* 2018;19:1140–5.
9. Dar P, Karmin I, Einstein MH. Arteriovenous malformations of the uterus: Long-term follow-up. *Gynecol Obstet Invest* 2008;66(3):157–61.
10. Ho CY, Seow KM, Huang LW, Tsai YL. Fertility outcomes following pelvic embolization in women with acquired uterine arteriovenous malformation. *Taiwan J Obstet Gynecol* 2017;56(6):831–5.
11. Vilos AG, Vilos GA, Hollett-Caines J, Rajakumar C, Garvin G, Kozak R. Uterine artery embolization for uterine arteriovenous malformation in five women desiring fertility: Pregnancy outcomes. *Hum Reprod* 2015;30(7):1599–605.
12. Soeda S, Kyojuka H, Suzuki S, Yasuda S, Nomura Y, Fujimori K. Uterine artery embolization for uterine arteriovenous malformation is associated with placental abnormalities in the subsequent pregnancy: Two cases report. *Fukushima J Med Sci* 2014;60(1):86–90.
13. Nasu K, Nishida M, Yoshimatsu J, Narahara H. Ectopic pregnancy after successful treatment with percutaneous transcatheter uterine arterial embolization for congenital uterine arteriovenous malformation: A case report. *Arch Gynecol Obstet* 2008;278(2):171–2.
14. Timmerman D, Van den Bosch T, Peeraer K, et al. Vascular malformations in the uterus: Ultrasonographic diagnosis and conservative management. *Eur J Obstet Gynecol Reprod Biol* 2000;92(1):171–8.

15. Delplanque S, Le Lous M, Proisy M, et al. Fertility, pregnancy, and clinical outcomes after uterine arteriovenous malformation management. *J Minim Invasive Gynecol* 2019;26(1):153–61.
16. Kudesia R, Wu H, Hunter Cohn K, et al. The effect of female body mass index on in vitro fertilization cycle outcomes: A multi-center analysis. *J Assist* 2018;35(11):2013–23.
17. ACOG Practice Bulletin No. 156: Obesity in pregnancy. *Obstet Gynecol* 2015;126(6):e112–26.
18. Majmudar B, Ghanee N, Horowitz IR, Graham D. Uterine arteriovenous malformation necessitating hysterectomy with bilateral salpingo-oophorectomy in a young pregnant patient. *Arch Pathol Lab Med* 1998;122(9):842–5.

Author Contributions

Brooke Malia Fenske – Design of the work, Drafting the work, Revising the work critically for important intellectual content, Final approval of the version to be published, Agree to be accountable for all aspects of the work in ensuring that questions related to the accuracy or integrity of any part of the work are appropriately investigated and resolved

Jennifer Marie Burgart – Design of the work, Drafting the work, Revising the work critically for important intellectual content, Final approval of the version to be published, Agree to be accountable for all aspects of the work in ensuring that questions related to the accuracy or integrity of any part of the work are appropriately investigated and resolved

Meaghan Shanahan – Conception of the work, Revising the work critically for important intellectual content, Final approval of the version to be published, Agree to be accountable for all aspects of the work in ensuring that questions related to the accuracy or integrity of any part of the work are appropriately investigated and resolved

Guarantor of Submission

The corresponding author is the guarantor of submission.

Source of Support

None.

Consent Statement

Written informed consent was obtained from the patient for publication of this article.

Conflict of Interest

Authors declare no conflict of interest.

Data Availability

All relevant data are within the paper and its Supporting Information files.

Copyright

© 2020 Brooke Malia Fenske et al. This article is distributed under the terms of Creative Commons Attribution License which permits unrestricted use, distribution and reproduction in any medium provided the original author(s) and original publisher are properly credited. Please see the copyright policy on the journal website for more information.

Access full text article on other devices



Access PDF of article on other devices





INTERNATIONAL JOURNAL OF
CASE REPORTS AND IMAGES



VIDEO JOURNAL OF
CLINICAL RESEARCH



VIDEO JOURNAL OF
BIOMEDICAL SCIENCE



INTERNATIONAL JOURNAL OF
HEPATOBIILIARY AND
PANCREATIC DISEASES



INTERNATIONAL JOURNAL OF
BLOOD TRANSFUSION AND
IMMUNOHEMATOLOGY



EDORIUM JOURNAL OF
OPHTHALMOLOGY



Submit your manuscripts at
www.edoriumjournals.com



EDORIUM JOURNAL OF
MEDICINE



EDORIUM JOURNAL OF
CARDIOTHORACIC AND
VASCULAR SURGERY



JOURNAL OF CASE REPORTS
AND IMAGES IN ORTHOPEDICS
AND RHEUMATOLOGY



EDORIUM JOURNAL OF
PSYCHOLOGY



EDORIUM JOURNAL OF
CELL BIOLOGY



JOURNAL OF CASE REPORTS AND IMAGES IN
DENTISTRY



EDORIUM JOURNAL OF
CANCER



EDORIUM JOURNAL OF
PSYCHIATRY



JOURNAL OF CASE REPORTS AND
IMAGES IN INFECTIOUS DISEASES



EDORIUM JOURNAL OF
ANATOMY AND EMBRYOLOGY



EDORIUM JOURNAL OF
SURGERY



JOURNAL OF CASE REPORTS
AND IMAGES IN PATHOLOGY



EDORIUM JOURNAL OF
ANESTHESIA