

CASE REPORT

PEER REVIEWED | OPEN ACCESS

Histopathologic diagnosis of aggressive angiomyxoma following removal of an asymptomatic, stable vulvar mass

Megan McNitt, Laura Collins, Yuliya Malayev

ABSTRACT

Introduction: Aggressive angiomyxoma (AAM) is a rare, locally aggressive, benign tumor usually found in the female pelvis. **Case Report:** We present a 42-year-old Caucasian female undergoing removal of a non-enlarging, painless vulvar mass at time of hysteroscopic endometrial ablation for abnormal uterine bleeding. The patient had a past medical history notable for multiple malignant melanomas. Past surgical history included three low transverse cesarean sections, postpartum tubal ligation, and three wide excisions of melanomas. Family history was negative for dermatologic disease or cancers. The mass had been present for over two years; she desired removal for cosmetic purposes. At the time of surgery, the patient was asymptomatic and physical examination revealed a soft, mobile, approximately 2 cm, non-tender right labial mass. Previous ultrasound report described the mass as 2 × 2 cm and solid-appearing. During the surgery, a 5 × 2.6 × 1.4 cm irregular mass with soft, spongy contents was removed intact via incision followed by blunt and sharp dissection. Pathology of the specimen revealed AAM, with extension of tumor to the surgical margins. Histology and immunohistochemistry reports

were consistent with previous descriptions of AAM tumors. **Conclusion:** While AAM is uncommon, the diagnosis should be considered for any patient presenting with an asymptomatic growth in the vulvovaginal region. Treatment should involve surgical excision, and the patient should be closely followed for recurrence. The case reported here is a unique presentation of a small, stable AAM in a patient with a history of multiple episodes of malignant melanoma in the past.

Keywords: Aggressive angiomyxoma, Asymptomatic, Benign, Vulva

How to cite this article

McNitt M, Collins L, Malayev Y. Histopathologic diagnosis of aggressive angiomyxoma following removal of an asymptomatic, stable vulvar mass. J Case Rep Images Obstet Gynecol 2020;6:100057Z08MM2020.

Article ID: 100057Z08MM2020

doi: 10.5348/100057Z08MM2020CR

Megan McNitt¹, Laura Collins², Yuliya Malayev³

Affiliations: ¹4th Year Medical Student, Wayne State University, School of Medicine, Detroit, Michigan, United States of America; ²MD, Obstetrics-Gynecology, Detroit Medical Center/Wayne State University, Detroit, Michigan, United States of America; ³DO, Obstetrics-Gynecology, Detroit Medical Center/Wayne State University, Commerce Charter Township, Michigan, United States of America.

Corresponding Author: Laura Collins, MD, 3876 Thomas Ave, Berkley, Michigan 48072, United States of America; Email: lcollins@med.wayne.edu

Received: 21 September 2019

Accepted: 03 December 2019

Published: 24 January 2020

INTRODUCTION

Aggressive angiomyxoma (AAM) is a locally aggressive, benign tumor usually found in the female pelvis. It was first described in 1983 by Steeper and Rossi, with approximately 350 cases reported since [1]. It tends to be slow-growing, with a high recurrence rate and local infiltration into neighboring tissues [1–4]. We describe a 42-year-old woman who presented for removal of a vulvar mass of two years duration for cosmetic reasons, with resultant pathology revealing AAM.

CASE REPORT

A 42-year-old Caucasian female, G3P3003, was scheduled for hysteroscopic endometrial ablation for abnormal uterine bleeding, with removal of an asymptomatic vulvar mass which had been present for two years. The mass was approximately 2 cm by palpation, non-enlarging, and painless. She desired removal for cosmetic purposes.

Her past medical history included malignant melanomas of the abdomen, back, face, and toenail. Past surgical history included three low transverse cesarean sections, postpartum tubal ligation, and wide excision of melanomas in 2009 (abdomen), 2011 (back), 2012 (right toenail), and 2018 (face). Family history was significant for breast cancer in paternal grandmother and diabetes mellitus in mother; no history of dermatologic disease or cancers.

At time of surgery, the patient was without complaints. Physical examination was unremarkable, with exception of the right labial mass. The mass was soft, mobile, non-tender. Previous ultrasound report described the mass as 2 × 2 cm and solid-appearing (Figure 1). The patient was taken to the operating room where an uncomplicated hysteroscopy with curettage and endometrial ablation was performed. The mass was removed via incision overlying the mass at the junction between the labia minora and majora. It was removed intact with blunt and sharp dissection, and the resultant defect was closed in two layers, with removal of excessive labial skin. The mass measured 5 × 2.6 × 1.4 cm in size with irregular borders and soft, spongy contents (Figure 2). The patient tolerated the procedure well and was discharged home that day.

Pathology of the specimen reported an AAM, with extension of the tumor to the margins of resection. Grossly, the tissue was pink-gray in color, lobulated, rubbery, and glistening with no evidence of necrosis or hemorrhage. The mass was a monotonous and hypocellular neoplasm composed of widely spaced bland spindle cells with inconspicuous cytoplasm. Cells were surrounded by myxoid matrix with scattered thin collagen fibrils and thin and thick walled vessels of variable sizes (Figure 3). There was no necrosis nor increased or atypical mitoses in the pathological specimen (Figure 4). Immunohistochemistry was positive for vimentin, estrogen receptor and CD34 and negative for S-100, CD117/C-kit, desmin and MUC4.

DISCUSSION

Described in 1983 by Steeper and Rossi, AAM is a rare mesenchymal tumor of the vulvovaginal or buttock region [2, 3]. These tumors tend to occur in reproductive-aged women and most commonly present as a painless growth in the genital region. The nonspecific appearance often leads to misdiagnosis for Bartholin's cyst, lipoma, labial cyst, hernia, or Gartner's duct cyst. While the

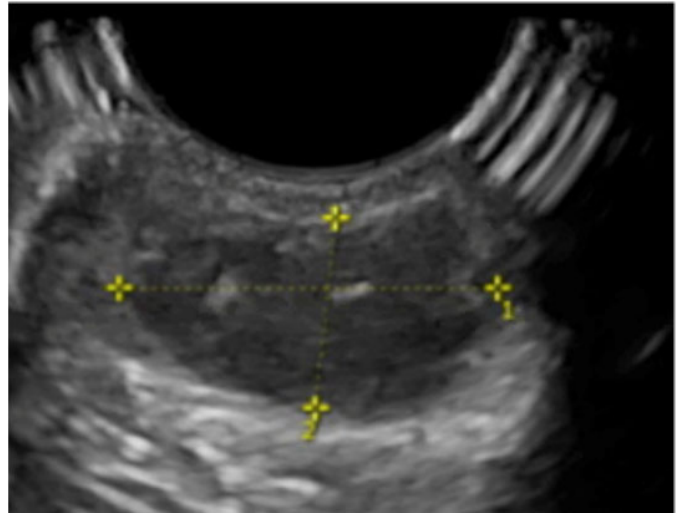


Figure 1: Ultrasound image of a solid-appearing vulvar mass measuring 2 × 2 cm.

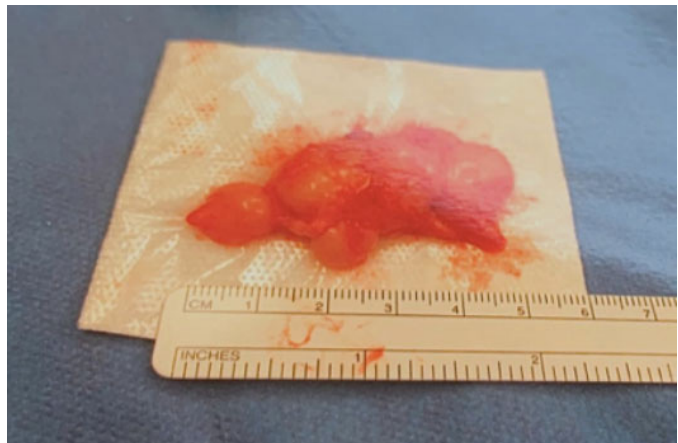


Figure 2: Surgical specimen following resection of vulvar mass. Gelatinous, poorly circumscribed tissue measuring 5 × 2 cm.

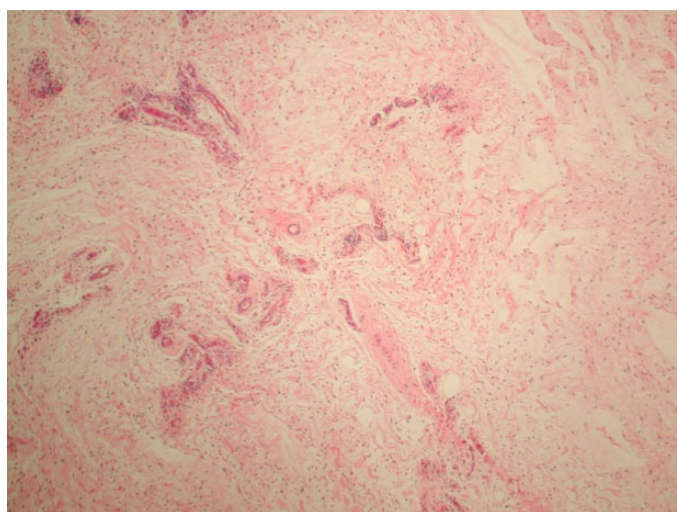


Figure 3: Low-power magnification (100×) of H&E stained pathological specimen showing a spindle cell neoplasm with low cellularity, myxoid matrix, and variably sized thin and thick walled vessels.

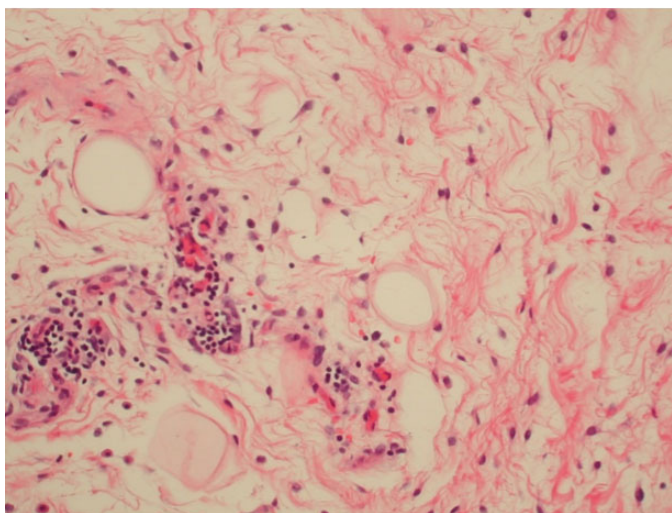


Figure 4: High-power magnification (400×) of H&E stained pathological specimen showing widely spaced-bland spindle cells with inconspicuous cytoplasm. There is no necrosis present and no increased or atypical mitoses.

etiology of AAM is unknown, Nucci et al. demonstrated that a chromosome 12 translocation may be present in some cases of AAM [5]. Tumors are thought to be hormonally dependent; most are positive for estrogen and progesterone receptors. Orfanelli et al. reinforced this theory by describing rapid growth of an AAM during pregnancy, with spontaneous regression in the postpartum period [6].

Aggressive angiomyxoma tumors are considered benign, with low malignant potential. However, tumors tend to be locally aggressive, with invasion into surrounding tissue. This may lead to displacement, without invasion, of the neighboring organs such as rectum, vagina, and bladder [4]. Additionally, complete resection is often difficult to achieve due to infiltrative, poorly circumscribed margins. There are a few case reports published that describe metastasis to the lungs, vena cava, and right atrium [4]. Aggressive angiomyxoma also has a high recurrence rate of 25–47%, with a recurrence timeline of 2–24 months after initial surgery [1, 2]. Recurrence seems to be independent of extent of surgical resection, as there has been no described relationship between surgical margins and recurrence risk [1].

Diagnosis can be attempted with imaging modalities such as ultrasound, computed tomography (CT) or magnetic resonance imaging (MRI), although there are no current guidelines. In a case report involving eight patients, Zhao et al. published the most thorough description of ultrasonographic appearance of AAM [7]. These masses have increased vascularity on color Doppler and are described as hypoechoic, with swirls of iso- or hyperechoic parts due to myxoid components. The tumors also tend to have fingerlike projections into neighboring tissue, demonstrating the aggressive and invasive nature. Upon dissection of AAM tumors, the

tissue is soft and rubbery, with deformity upon ultrasound probe compression [7]. Due to ultrasound's high reliance on user ability, CT and MRI have also been studied as a diagnostic tool. While MRI can be very sensitive for AAM when using contrast enhancement, CT is not very specific. On CT, AAM tends to be hypodense to muscle and can have cystic and solid components [4].

Aggressive angiomyxoma tumors have the characteristic appearance of a large, infiltrative, gelatinous vulvar mass. While slow-growing, patients often note increase in size over time with masses reaching up to 20 cm in size [2, 6]. Additionally, as they are painless and asymptomatic, they tend to achieve this large size prior to management and up to 25% present as pedunculated lesions. Women with an AAM tumor may present with pelvic fullness, pain in the region of the tumor, and/or dyspareunia [4]. On microscopic appearance, AAM is described as a matrix of spindle and stellate cells separated by myxoid stroma [3]. On histopathologic reports, AAM tumors are typically positive for CD34, SMA, desmin, vimentin, ER, and PR while negative for S-100, which is consistent with the findings on pathology for the mass presented in this case report [4].

Treatment for AAM is currently aimed at wide surgical excision. However, as most tumors are ER+ or PR+, hormonal treatment is being investigated as an adjunct or replacement to surgery. There is no current data showing that wide margins lead to better outcomes, despite current practices [1, 6]. A case report by Kanao et al. showed that combining laparoscopic and open perineal approaches to remove a vulvar AAM might be an acceptable option to avoid wide surgical excision [8]. Regardless, the mass should be excised once identified to avoid further growth and the need for more extensive wide excision with poorer cosmetic results in the future. There are currently no guidelines for the postoperative follow-up. However, according to Das et al., patients should be followed for at least 15 years with yearly physical exams and potentially with MRI to rule out recurrence [9]. Some studies have shown benefit with preoperative treatment by radiation therapy or hormonal antagonists such as GnRH agonists in order to shrink the tumor to avoid extensive resection [1, 2]. Currently, hormonal treatment with GnRH agonists and/or selective estrogen receptor modulators (SERMs) have been shown to be successful in conjunction with surgery or in the treatment of recurrent tumors [10, 11]. There are no studies indicating the length of response to hormonal treatment after completion of therapy [10]. Studies have shown a high rate of recurrence once hormonal treatment is stopped, therefore close follow-up with imaging should be undertaken for patients with AAM [12].

The case reported here involves the removal of an undiagnosed, asymptomatic mass for cosmetic reasons. This is a unique presentation of a small AAM in a patient with a history of multiple episodes of malignant melanoma in the past. There is no known association of AAM to malignant melanoma, though it is a notable

co-diagnosis in this case. Our patient had a tumor much smaller than those typically reported, measuring only 5 cm following resection. Of note, prior to resection the tumor was believed to be only 2 × 2 cm both from palpation and ultrasound report. The patient reported that the size of the growth was stable over the course of two years, rather than slow-growing, though this could be related to false interpretation of size. Because of the aggressive and high recurrence rate for AAMs, this patient will continue to have close follow-up, including MRI evaluation.

CONCLUSION

While AAM is uncommon, the diagnosis should be considered for any patient presenting with an asymptomatic growth in the vulvovaginal region. Treatment should involve surgical excision, and the patient should be closely followed for recurrence.

REFERENCES

- Sutton BJ, Laudadio J. Aggressive angiomyxoma. *Arch Pathol Lab Med* 2012;136(2):217–21.
- Chen H, Zhao H, Xie Y, Jin M. Clinicopathological features and differential diagnosis of aggressive angiomyxoma of the female pelvis: 5 case reports and literature review. *Medicine (Baltimore)* 2017;96(20):e6820.
- Steeper TA, Rosai J. Aggressive angiomyxoma of the female pelvis and perineum. Report of nine cases of a distinctive type of gynecologic soft-tissue neoplasm. *Am J Surg Pathol* 1983;7(5):463–75.
- Brzezinska BN, Clements AE, Rath KS, Reid GC. A persistent mass: A case of aggressive angiomyxoma of the vulva. *Gynecol Oncol Rep* 2018;24:15–7.
- Nucci MR, Weremowicz S, Neskey DM, et al. Chromosomal translocation t(8;12) induces aberrant HMGIC expression in aggressive angiomyxoma of the vulva. *Genes Chromosomes Cancer* 2001;32(2):172–6.
- Orfanelli T, Kim CS, Vitez SF, Van Gorp J, Misra N. A case report of aggressive angiomyxoma in pregnancy: Do hormones play a role? *Case Rep Obstet Gynecol* 2016;2016:6810368.
- Zhao CY, Su N, Jiang YX, Yang M. Application of ultrasound in aggressive angiomyxoma: Eight case reports and review of literature. *World J Clin Cases* 2018;6(14):811–9.
- Kanao H, Aoki Y, Tanigawa T, et al. En bloc resection of an aggressive angiomyxoma by a novel combination laparoscopic and open perineal approach. *J Minim Invasive Gynecol* 2019;26(4):598–9.
- Das BP, Baruah D, Medhi KB, Talukder B. An aggressive angiomyxoma of vulva - A rare entity: A case report. *J Midlife Health* 2016;7(3):140–3.
- Shinohara N, Nonomura K, Ishikawa S, Seki H, Koyanagi T. Medical management of recurrent aggressive angiomyxoma with gonadotropin-releasing hormone agonist. *Int J Urol* 2004;11(6):432–5.
- Palomba S, Oppedisano R, Annunziata G, Zullo F, Amorosi A. Leuprolide acetate depot plus high-dose raloxifene hydrochloride before and after surgery for recurrent vaginal aggressive angiomyxoma: A case report. *Gynecol Oncol* 2011;123(1):172–3.
- Song M, Glasgow M, Murugan P, Rivard C. Aggressive angiomyxoma of the vulva and bladder. *Obstet Gynecol* 2017;130(4):885–8.

Acknowledgments

The authors would like to thank Dr. Aulicino, the pathologist, for his help on this case.

Author Contributions

Megan McNitt – Design of the work, Acquisition of data, Drafting the work, Revising the work critically for important intellectual content, Final approval of the version to be published, Agree to be accountable for all aspects of the work in ensuring that questions related to the accuracy or integrity of any part of the work are appropriately investigated and resolved

Laura Collins – Conception of the work, Design of the work, Analysis of data, Drafting the work, Revising the work critically for important intellectual content, Final approval of the version to be published, Agree to be accountable for all aspects of the work in ensuring that questions related to the accuracy or integrity of any part of the work are appropriately investigated and resolved

Yuliya Malayev – Acquisition of data, Interpretation of data, Revising the work critically for important intellectual content, Final approval of the version to be published, Agree to be accountable for all aspects of the work in ensuring that questions related to the accuracy or integrity of any part of the work are appropriately investigated and resolved

Guarantor of Submission

The corresponding author is the guarantor of submission.

Source of Support

None.

Consent Statement

Written informed consent was obtained from the patient for publication of this article.

Conflict of Interest

Authors declare no conflict of interest.

Data Availability

All relevant data are within the paper and its Supporting Information files.

Copyright

© 2020 Megan McNitt et al. This article is distributed under the terms of Creative Commons Attribution

License which permits unrestricted use, distribution and reproduction in any medium provided the original author(s) and original publisher are properly credited.

Please see the copyright policy on the journal website for more information.

Access full text article on
other devices



Access PDF of article on
other devices





INTERNATIONAL JOURNAL OF
CASE REPORTS AND IMAGES



VIDEO JOURNAL OF
CLINICAL RESEARCH



VIDEO JOURNAL OF
BIOMEDICAL SCIENCE



INTERNATIONAL JOURNAL OF
HEPATOBIILIARY AND
PANCREATIC DISEASES



INTERNATIONAL JOURNAL OF
BLOOD TRANSFUSION AND
IMMUNOHEMATOLOGY



EDORIUM JOURNAL OF
OPHTHALMOLOGY



Submit your manuscripts at
www.edoriumjournals.com



EDORIUM JOURNAL OF
MEDICINE



EDORIUM JOURNAL OF
CARDIOTHORACIC AND
VASCULAR SURGERY



JOURNAL OF CASE REPORTS
AND IMAGES IN ORTHOPEDICS
AND RHEUMATOLOGY



EDORIUM JOURNAL OF
PSYCHOLOGY



EDORIUM JOURNAL OF
CELL BIOLOGY



JOURNAL OF CASE REPORTS AND IMAGES IN
DENTISTRY



EDORIUM JOURNAL OF
CANCER



EDORIUM JOURNAL OF
PSYCHIATRY



JOURNAL OF CASE REPORTS AND
IMAGES IN INFECTIOUS DISEASES



EDORIUM JOURNAL OF
ANATOMY AND EMBRYOLOGY



EDORIUM JOURNAL OF
SURGERY



JOURNAL OF CASE REPORTS
AND IMAGES IN PATHOLOGY



EDORIUM JOURNAL OF
ANESTHESIA