

CASE REPORT

PEER REVIEWED | OPEN ACCESS

Hyperfunctioning benign struma ovarii in a young patient with Graves' disease: Challenges in fertility-sparing management

Lee Shi Hui, Qin Yan, Lim Shau Khng

ABSTRACT

Introduction: Concomitant Graves' disease with struma ovarii is a rare condition, with 18 cases reported to date. Preoperative diagnosis of struma ovarii is challenging due to nonspecific imaging features. Many patients are taken for extensive staging laparotomy in view of concerns of ovarian malignancy, however, benign struma ovarii can be treated satisfactorily by cystectomy or oophorectomy. **Case Report:** We present a case of a 33-year-old Chinese lady with known Graves' disease, who was incidentally found to have a complex solid-cystic right ovarian cyst on pelvic ultrasound. Magnetic resonance imaging of the pelvis was suspicious for primary epithelial ovarian neoplasm. In view of her young age, she was keen for fertility-sparing surgery. She underwent laparotomy ovarian cystectomy with frozen section, which showed benign struma ovarii. Postoperatively, she remained clinically euthyroid without further medical treatment. Postoperative technetium 99m showed no residual ectopic thyroid tissue in the pelvis. **Conclusion:** This could be the sixth case in the world where conservative surgery was used in a patient with concomitant Graves' disease with struma ovarii.

Keywords: Fertility-sparing surgery, Functioning struma ovarii, Graves' disease

How to cite this article

Lee SH, Qin Y, Lim SK. Hyperfunctioning benign struma ovarii in a young patient with Graves' disease: Challenges in fertility-sparing management. J Case Rep Images Obstet Gynecol 2020;6:100059Z08LH2020.

Article ID: 100059Z08LH2020

doi: 10.5348/100059Z08LH2020CR

INTRODUCTION

Struma ovarii is a rare form of ovarian germ cell tumor, defined by the presence of thyroid tissue >50% of the overall mass. It accounts for 0.5–1.0% of all ovarian tumors [1]. It is mostly benign, with malignant transformation seen in approximately 5% of struma ovarii [2]. Majority of these patients are asymptomatic, with a small group presenting with pelvic mass, compressive symptoms, ascites, or thyrotoxicosis [3]. Thyrotoxicosis from struma ovarii has been reported in 8–10% of patients [4], and is noted to be rare for tumors of <3 cm [5]. Concomitant Graves' disease with struma ovarii is a rare condition, with 18 cases [3, 6, 7], 15 of which were benign, reported to date.

We report a case of a young lady with known Graves' disease, presenting with a functioning benign struma ovarii. She underwent laparotomy ovarian cystectomy, and remained clinically euthyroid without further medical treatment.

CASE REPORT

A 33-year-old nulliparous Chinese woman presented with an incidental finding of complex right ovarian cyst. She has a background of Graves' disease which

Lee Shi Hui¹, Qin Yan², Lim Shau Khng³

Affiliations: ¹Resident, Department of Obstetrics and Gynaecology, Singapore General Hospital, Singapore; ²Senior Consultant, Department of Internal Medicine, Singapore General Hospital, Singapore; ³Senior Consultant, Department of Obstetrics and Gynaecology, Singapore General Hospital, Singapore.

Corresponding Author: Lee Shi Hui, Academia, Level 5, 20 College Rd, Singapore 169856, Singapore; Email: shihui.lee@mohh.com.sg

Received: 18 March 2020

Accepted: 12 May 2020

Published: 22 May 2020

was diagnosed since 2012. She was positive for thyroid stimulating immunoglobulin (825%; normal 50–179%), thyroid stimulating hormone (TSH) receptor antibody (18.4 IU/L; normal 0–1.5 IU/L), and anti-thyroid microsomal antibody positive (titer 1:400). Ultrasound thyroid showed heterogenous and hypervascular thyroid, suggestive of Graves' disease. She was started on carbimazole (CMZ) since diagnosis, but became noncompliant in the recent years, resulting in one admission for thyrotoxicosis in 2017.

She was referred to the gynecology clinic in April 2019 for an incidental finding of a right ovarian cyst. Ultrasound pelvis revealed a right ovarian multiloculated solid cystic mass measuring 8.9 × 5.8 × 8.0 cm. One of the locules measured 5.2 × 4.4 × 5.0 cm and it contained low-level echoes. There were a few irregular solid areas with the largest measuring 3.4 × 2.5 × 1.6 cm. Color Doppler detected moderate intratumoral flow (Figure 1).

A magnetic resonance imaging (MRI) of the pelvis was done to better characterize the cyst, and it revealed a multiloculated right ovarian cystic lesion with thick irregular enhancing septations, suspicious for primary epithelial ovarian neoplasm (Figure 2). There was no ascites, and no enlarged pelvic lymph node. Left ovary and uterus were unremarkable.

Ovarian tumor markers, including beta-human chorionic gonadotropin, alpha-fetoprotein, cancer antigen 125, carcinoembryonic antigen were all normal. Thyroid function at that time showed thyrotoxicosis, with thyroxine (T4) levels at 19.1 pmol/L (normal range 8.8–14.4 pmol/L) and TSH of <0.01 mU/L (normal range 0.65–3.7 mU/L).

She was offered surgery in view of suspicion of ovarian malignancy. Given her young age and fertility status, she was keen for fertility-sparing surgery. Preoperatively, her thyroid function was optimized with CMZ to reduce risk of thyroid storm. She underwent laparotomy ovarian cystectomy with frozen section. Intraoperative findings noted a right ovarian cyst which was 10 cm in diameter with solid-cystic areas. Left ovary, bilateral tubes, and uterus were normal (Figure 3).

Uncomplicated cystectomy was done, and frozen section revealed teratomatous elements of thyroid follicles and squamous epithelium. Benign struma ovarii was confirmed on final histology (Figure 4), and peritoneal washings were negative for malignant cells. Postoperatively, her carbimazole dose was titrated according to her thyroid function, and was stopped three weeks after surgery. She remained clinically euthyroid, with thyroid function tests suggestive of subclinical hyperthyroidism with normal T4 levels (Figure 5) and suppressed TSH levels (Figure 6). Postoperative technetium 99m (Tc-99m) pertechnetate scan shows normal thyroid gland and no abnormal focus of tracer uptake in the pelvis, indicating that there was no residual pelvic thyroid tissue.

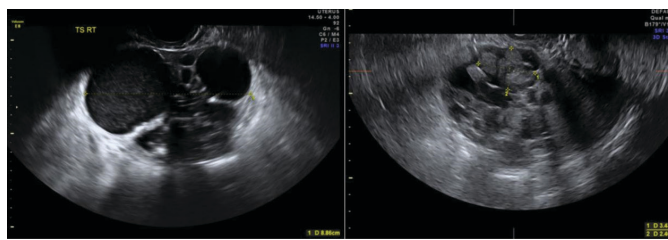


Figure 1: Ultrasound images of right ovarian multiloculated cyst measuring 8.9 cm (left), with irregular solid area, the largest measuring 3.4 cm (right).

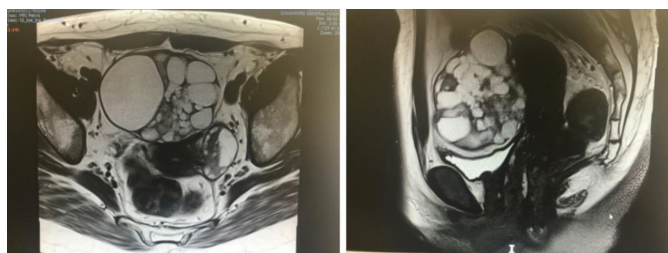

Figure 2: MRI of the right ovarian cyst in axial (left) and sagittal view (right).

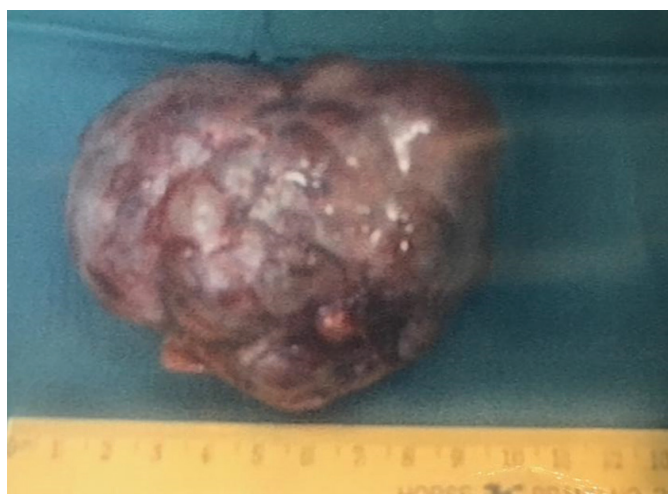

Figure 3: Specimen of the right ovarian cyst.

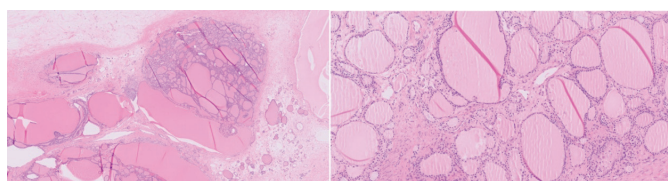


Figure 4: Thyroid follicles of varying sizes, low power magnification [2×] (left). Thyroid follicles lined by bland follicular cells, medium power magnification [10×] (right).

DISCUSSION

Struma ovarii is difficult to diagnose preoperatively, as it does not have any specific clinical, radiological, or serum markers [1]. Ultrasound features of “struma pearl” (well-defined, solid tissue with a smooth margin that is vascularized on Doppler study) are uncommon and

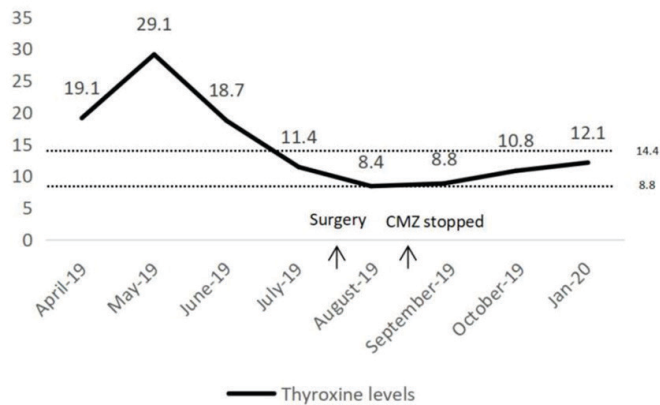


Figure 5: Thyroxine levels over 10 months (normal range 8.8–14.4 pmol/L).

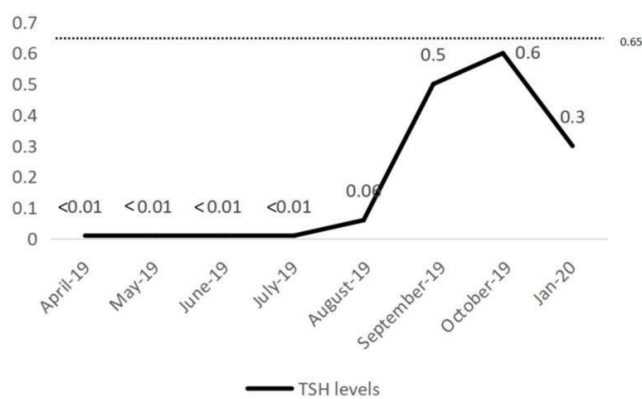


Figure 6: Thyroid stimulating hormone levels over 10 months (normal range 0.65–3.7 mU/L).

difficult to interpret [8]. Moreover, struma ovarii can mimic ovarian malignancy clinically, when it presents as a complex ovarian mass. Literature reports that up to a third of benign cases can have concomitant ascites, raising suspicion of ovarian malignancy [9]. Indeed, this case reflects the challenges of preoperative diagnosis of struma ovarii. Our patient's imaging findings raised concerns for malignancy, with the ultrasound features of her ovarian cyst gave an International Ovarian Tumor Analysis (IOTA) score of 6.4% likelihood ratio of malignancy. Magnetic resonance imaging pelvis was also suggestive of an ovarian neoplasm.

Struma ovarii commonly occurs in the fourth to sixth decade of life, with most patients in the reproductive age group where fertility is of concern [10]. Benign struma ovarii can be treated satisfactorily by cystectomy or oophorectomy [8, 11], with no cases of recurrence reported in previous reviews [1, 11–13]. Laparoscopic surgery has been recommended for given the shorter recovery time and lower morbidity [12, 13]. However, in many other cases, patients are taken for radical surgery, with extensive staging laparotomy for suspected ovarian malignancy. In only 1 of the previous reported cases was surgery done via laparoscopic route [6]. Of the 15 benign

cases, only 5 patients underwent conservative surgery with cystectomy or oophorectomy. Kung et al. described a case of torted struma ovarii presenting at term pregnancy, and the patient underwent ovarian cystectomy during her caesarean section [14]. The other four cases had high suspicion of struma ovarii due to preoperative diagnosis on scintigraphy [6, 15–17].

Our patient is one of the younger reported cases of concomitant Graves' disease with struma ovarii, with previous cases ranged from 26 to 78 years old. Hence, fertility and ovarian preservation was of great importance in our patient. Risk and benefit of ovarian cystectomy versus oophorectomy was discussed with our patient, and she was keen for cystectomy. Decision for laparotomy was made in view of the suspicious radiological features present on preoperative imaging, reducing risk of inadvertent rupture with spillage and subsequent metastatic seeding, as well as for allowing further staging procedures if on-table frozen section histology was positive.

Hyperfunctioning struma ovarii is uncommon, occurring in 8–10% of patients with struma ovarii [4]. Concomitant Graves' disease with struma ovarii is rare, with 18 cases reported thus far in literature [3, 6, 7]. Diagnosis of hyperfunctioning struma ovarii tends to be masked by Graves' disease, and can be delayed by up to 20 years [3, 18]. Only in 3 of the 18 cases were Graves' disease and struma ovarii diagnosed simultaneously [6, 19, 20]. Our patient was initially diagnosed with Graves' disease in 2012 due to thyrotoxicosis, positive thyroid antibodies, and findings on ultrasound thyroid. She was only found to have a hyperfunctioning struma ovarii seven years later. Her abnormal thyroid function prior to surgery was attributed to non-compliance to her anti thyroid medications. This was the reason why extrathyroidal thyrotoxicosis was not initially suspected.

There are two postulated mechanism behind hyperfunctioning struma ovarii: (1) Circulating thyroid stimulating antibodies in Graves' disease results in the growth of thyroid tissue present in the ovary, causing thyroid hormone secretion, and/or (2) Struma ovarii itself may have autonomous function, without the existence of Graves' disease [3]. Thyroid production in patients with concomitant hyperthyroidism and struma ovarii can be from the hyperfunctioning thyroid gland alone, struma ovarii alone, or from both the thyroid gland and the struma ovarii [18]. In our patient, she became euthyroid shortly after surgery without any medications. We postulate that the main source of thyroid hormone secretion was from her struma ovarii. This would explain the resolution and normalization of thyroid hormones after surgical resection of the ovarian tumor.

CONCLUSION

In conclusion, we present a unique case of concomitant Graves' disease and benign struma ovarii where the patient subsequently became euthyroid after surgical

resection of struma ovarii. This may be the sixth case in the world where conservative surgery was used. This case reflects the challenges in management of patients keen for fertility-sparing surgery. Clinicians must bear in mind the differential diagnosis of functioning struma ovarii in patients with thyrotoxicosis. Preoperative optimization of thyroid function is essential in preventing thyroid storm perioperatively. Conservative surgery for struma ovarii is appropriate, hence preoperative diagnosis should be obtained whenever possible to aid in surgical planning. Postoperatively, thyroid function should be closely monitored for optimal titration of anti-thyroid medications.

REFERENCES

1. Yoo SC, Chang KH, Lyu MO, Chang SJ, Ryu HS, Kim HS. Clinical characteristics of struma ovarii. *J Gynecol Oncol* 2008;19(2):135–8.
2. Rosenblum NG, LiVolsi VA, Edmonds PR, Mikuta JJ. Malignant struma ovarii. *Gynecol Oncol* 1989;32(2):224–7.
3. Sitasuwan T, Hanamornroongruang S, Peerapatdit T, Thongtang N. Coexistence of Graves' disease and unilateral functioning struma ovarii: A case report. *BMC Endocr Disord* 2015;15:68.
4. Davies TF, Laurberg P, Bahn RS. Hyperthyroid disorders. In: Melmed S, Polonsky KS, Larsen PR, Kronenberg HM, editors. *Williams Textbook of Endocrinology*. 13ed. Philadelphia: Elsevier; 2016. p. 369–415.
5. Kempers RD, Dockerty MB, Hoffman DL, Bartholomew LG. Struma ovarii—ascitic, hyperthyroid, and asymptomatic syndromes. *Ann Intern Med* 1970;72(6):883–93.
6. Alexander LD, Leckie A, Burton K, Jain L, Geary M, Yu C. Co-existing Graves disease with benign struma ovarii: A case report. *AACE Clinical Case Reports* 2018;4(6):e463–6.
7. Tay WL, Loh WJ, Lee LAL, Chng CL. Persistent hyperthyroidism and de novo Graves' ophthalmopathy after total thyroidectomy. *Endocrinol Diabetes Metab Case Rep* 2017;2017: 17–0109.
8. Singh P, Lath N, Shekhar S, et al. Struma ovarii: A report of three cases and literature review. *J Midlife Health* 2018;9(4):225–9.
9. Amr SS, Hassan AA. Struma ovarii with pseudo-Meigs' syndrome: Report of a case and review of the literature. *Eur J Obstet Gynecol Reprod Biol* 1994;55(3):205–8.
10. Talerman A. Germ cell tumors of the ovary. Kurman RJ, editor. *Blaustein's Pathology of the Female Genital Tract*. 3ed. New York: Springer-Verlag; 2001. p. 967–1033.
11. Wang Y, Pan L, Huang H, Shen K, Wu M, Lang J. Clinical study on 68 cases with struma ovarii. [Article in Chinese]. *Zhonghua Fu Chan Ke Za Zhi* 2014;49(6):451–4.
12. Khediri Z, Mbarki C, Abdelaziz AB, Hsayoui N, Mezghenni S, Oueslati H. Struma ovarii: Clinical presentations of an uncommon tumor. *International Journal of Case Reports and Images* 2012;3(4):10–14.
13. Wee JYS, Li X, Chern BSM, Chua ISY. Struma ovarii: Management and follow-up of a rare ovarian tumour. *Singapore Med J* 2015;56(1):35–9.
14. Kung AW, Ma JT, Wang C, Young RT. Hyperthyroidism during pregnancy due to coexistence of struma ovarii and Graves' disease. *Postgrad Med J* 1990;66(772):132–3.
15. Mimura Y, Kishida M, Masuyama H, et al. Coexistence of Graves' disease and struma ovarii: Case report and literature review. *Endocr J* 2001;48(2):255–60.
16. Bartel TB, Juweid ME, O'dorisio T, Sivitz W, Kirby P. Scintigraphic detection of benign struma ovarii in a hyperthyroid patient. *J Clin Endocrinol Metab* 2005;90(6):3771–2.
17. Chiofalo MG, Misso C, Insabato L, Lastoria S, Pezzullo L. Hyperthyroidism due to coexistence of Graves' disease and struma ovarii. *Endocr Pract* 2007;13(3):274–6.
18. Anastasilakis AD, Ruggeri RM, Polyzos SA, et al. Coexistence of Graves' disease, papillary thyroid carcinoma and unilateral benign struma ovarii: Case report and review of the literature. *Metabolism* 2013;62(10):1350–6.
19. Bayot MR, Chopra IJ. Coexistence of struma ovarii and Graves' disease. *Thyroid* 1995;5(6):469–71.
20. Kano H, Inoue M, Nishino T, Yoshimoto Y, Arima R. Malignant struma ovarii with Graves' disease. *Gynecol Oncol* 2000;79(3):508–10.

Acknowledgments

We thank Dr. Wong Shing Lih from Department of Pathology, Singapore General Hospital, for his help in obtaining the histopathological slides for this patient.

Author Contributions

Lee Shi Hui – Conception of the work, Acquisition of data, Drafting the work, Final approval of the version to be published, Agree to be accountable for all aspects of the work in ensuring that questions related to the accuracy or integrity of any part of the work are appropriately investigated and resolved

Qin Yan – Conception of the work, Design of the work, Revising the work critically for important intellectual content, Final approval of the version to be published, Agree to be accountable for all aspects of the work in ensuring that questions related to the accuracy or integrity of any part of the work are appropriately investigated and resolved

Lim Shau Khng – Conception of the work, Design of the work, Revising the work critically for important intellectual content, Final approval of the version to be published, Agree to be accountable for all aspects of the work in ensuring that questions related to the accuracy or integrity of any part of the work are appropriately investigated and resolved

Guarantor of Submission

The corresponding author is the guarantor of submission.

Source of Support

None.

Consent Statement

Written informed consent was obtained from the patient for publication of this article.

Conflict of Interest

Authors declare no conflict of interest.

Data Availability

All relevant data are within the paper and its Supporting Information files.

Copyright

© 2020 Lee Shi Hui et al. This article is distributed under the terms of Creative Commons Attribution License which permits unrestricted use, distribution and reproduction in any medium provided the original author(s) and original publisher are properly credited. Please see the copyright policy on the journal website for more information.

Access full text article on
other devices



Access PDF of article on
other devices

