

# Stable lung function with pulmonary Langerhans cell histiocytosis in pregnancy

Ghamar Bitar, Philip Shlossman

## ABSTRACT

**Introduction:** Few studies have evaluated the effect of pulmonary Langerhans cell histiocytosis on lung function in pregnancy and the appropriate mode of delivery. **Case Series:** Case 1 details a young multiparous female affected by pulmonary Langerhans cell histiocytosis with the need for baseline oxygen therapy outside of pregnancy and fetus with severe growth restriction requiring delivery at term by cesarean section. Case 2 includes a young multiparous female with pulmonary Langerhans cell histiocytosis with an uncomplicated pregnancy course and delivery at term by cesarean section. **Conclusion:** In patients with pulmonary Langerhans cell histiocytosis, lung function typically remains stable in pregnancy. Interstitial lung disease may affect birth weight. There may be a recommendation for delivery by cesarean section to reduce pneumothorax risk.

**Keywords:** Cesarean section, High risk pregnancy, Langerhans cell histiocytosis, Low birth weight infant

### How to cite this article

Bitar G, Shlossman P. Stable lung function with pulmonary Langerhans cell histiocytosis in pregnancy. J Case Rep Images Obstet Gynecol 2020;6:100063Z08GB2020.

Article ID: 100063Z08GB2020

Ghamar Bitar<sup>1</sup>, Philip Shlossman<sup>2</sup>

**Affiliations:** <sup>1</sup>Department of Obstetrics & Gynecology, Christiana Care Health System, Newark, DE, USA; <sup>2</sup>Division of Maternal Fetal Medicine, Christiana Care Health System, Newark, DE, USA.

**Corresponding Author:** Ghamar Bitar, Department of Obstetrics & Gynecology, 4755 Oglethorpe-Stanton Road, Newark, DE 19718, USA; Email: Ghamar.Bitar@christianacare.org

Received: 24 April 2020

Accepted: 28 May 2020

Published: 13 July 2020

\*\*\*\*\*

doi: 10.5348/100063Z08GB2020CS

## INTRODUCTION

Langerhans cell histiocytosis (LCH) occurs when the body produces too many of one specific type of white blood cell, or Langerhans cells (histiocytes). This cancer can be present in one or multiple organ systems. Pulmonary Langerhans cell histiocytosis (PLCH) manifests as cystic interstitial lung disease. The disease is most common in children, but the incidence of the disease is estimated to be approximately 1–2 per 1000 adult patients [1, 2]. Risk factors for PLCH include cigarette smoking and a family history of cancer [3]. The diagnosis requires identification of Langerhans cell granulomas on lung biopsy. The standard of care for adults with the disease is to encourage smoking cessation, arrange chemotherapy, and consider lung transplant for patients with severe lung damage [2].

The presentation and course of PLCH has not been well characterized in pregnancy. It is important for clinicians to feel confident in counseling patients on possible complications in pregnancy, if any, including relevant recommendations for mode of delivery.

## CASE SERIES

### Case 1

A 28-year-old Gravida 3, Para 1011 female with history of tobacco use and Hepatitis C, on methadone therapy due to previous intravenous (IV) drug use, presented as a transfer of care to our hospital at 30 weeks gestation with newly diagnosed fetal growth restriction at less than the first percentile. The patient was undergoing ultrasound surveillance due to her history of PLCH and severe persistent asthma. Simultaneously during this transfer, there was concern for worsening lung function based on symptoms reported by the patient.

Prior obstetric history was unremarkable, with an uncomplicated gestation and full term vaginal delivery of an appropriately grown neonate. She had no

obstetric complaints on presentation and was admitted for continuous fetal monitoring in the setting of newly diagnosed growth restriction. After being counseled on the risks of possible delivery pending fetal monitoring, the patient received antenatal corticosteroids and opted for 12 hours of magnesium sulfate for fetal neuroprotection. The plan was for continuous fetal monitoring, continued maternal respiratory status monitoring, and repeat fetal biophysical assessment in 48 hours. Overall, fetal heart rate monitoring was reassuring.

In regard to the patient's lung disease, she had regular care established with a pulmonary specialist for severe persistent asthma and was diagnosed with PLCH by lung biopsy in 2016. She had no evidence of extrapulmonary disease involvement. The patient had a baseline need for 2 L of supplemental oxygen by nasal cannula, which was started prior to pregnancy for shortness of breath at rest. Pulmonary function testing prior to pregnancy documented her forced expiratory volume in one second/forced vital capacity (FEV<sub>1</sub>/FVC) at 51%, lower than the expected average adult value of 75%, indicating obstructive lung disease (likely related to her diagnosed asthma). The patient was managed on budesonide-formoterol, montelukast, and albuterol as needed. The plan was for chemotherapy after delivery.

On presentation, she expressed more shortness of breath at rest during the last month. Her clinical evaluation was normal, including clear lung exam and vital signs that were within appropriate range, evidenced by oxygen saturation on room air of 95–98%. Evaluation for increasing shortness of breath at rest in pregnancy was initiated. Maternal electrocardiogram and maternal echo were normal. Chest X-ray showed no acute lung process and lower extremity Doppler showed no signs of deep vein thrombosis. Pulmonary consult was placed and she was evaluated by her own pulmonologist who recommended repeating spirometry testing and continuing management with her current medications. Recommendations for delivery by cesarean section were also made due to the concern for spontaneous pneumothorax during vaginal delivery.

The patient had continuous fetal monitoring in the hospital for four days, at which time repeat biophysical profiles were 10/10 with an elevated S:D ratio in one umbilical artery Doppler study. Her O<sub>2</sub> saturation remained within normal limits for pregnancy (≥95%) on room air and with 2–3 L of oxygen by nasal cannula as needed with exertion. Repeat spirometry showed a stable FEV<sub>1</sub>/FVC value of 48%. The diffusion capacity was mildly reduced (DCLO), but similar to her baseline level. After spirometry testing, pulmonology concluded that her lung function was stable as compared to her baseline outside of pregnancy.

Given reassuring fetal status and stable maternal status, she was discharged with planned follow-up. At 33 weeks gestation, in the setting of less than the first percentile fetal growth restriction and absent end diastolic velocity on umbilical artery Doppler study, admission

was recommended for continuous fetal monitoring. Repeat Doppler studies a few days after admission were reassuring with no evidence of absent end diastolic velocity and only evidence of increased umbilical artery pulsatility index. She remained in the hospital with twice daily non-stress tests and three times weekly biophysical profiles until she delivered at 37 weeks gestation via uncomplicated primary low transverse cesarean section under spinal anesthesia. Neonatal Apgar scores were 8/9 at 1 and 5 minutes of life, with a birth weight of 2.02 kg. Placental pathology was notable for a focal villous infarct but otherwise normal. The patient has had no pulmonary follow-up since delivery.

## Case 2

A 27-year-old Gravida 4, Para 1021 transferred her care to our high risk obstetrics clinic at 12 weeks gestation with known PLCH. Past medical history was notable for moderate persistent asthma and Crohn's disease. The patient was a former smoker. She was diagnosed with PLCH in February of 2013 after lung biopsy but had been lost to care until current pregnancy. She was newly managed by a pulmonologist on formoterol-budesonide and albuterol as needed. Her pulmonary function testing at baseline was normal without any signs of obstructive or restrictive lung disease. At her new obstetric visit at 12 weeks of pregnancy, she noted respiratory symptoms requiring variable albuterol use, ranging from once a week to multiple times daily. The patient was scheduled for a detailed fetal anatomy ultrasound, as well as fetal growth ultrasounds starting at 28 weeks gestation given her diagnosis. She was informed of the recommendation for a primary cesarean section by her pulmonologist despite having a previously uncomplicated full term vaginal delivery.

At 24 and 28 weeks gestation, she reported dyspnea at rest during her obstetric visit. She reported checking her oxygen saturation at home via pulse oximetry and reporting results as 93–94% on room air. Pulse oximetry in the office both times was above 97% and goal of ≥95% was discussed. Notably, fetus was appropriately grown at the detailed anatomy ultrasound. Overnight pulse oximetry study was ordered by her pulmonologist due to reported symptoms. She presented for admission at 30 weeks gestation and an overnight oxygen study results demonstrated oxygen saturation greater than 95% for majority of the night. Given her persistent reporting of symptoms, and after counseling on oxygen therapy and side effects, the patient desired supplemental oxygen therapy for her own peace of mind.

The patient had no other obstetric or fetal issues during the remainder of her pregnancy, with an appropriately grown fetus. She continued to follow-up with pulmonology every four weeks without any change in her lung function. She presented for primary low transverse cesarean section at 37 weeks gestation under spinal anesthesia. Apgar scores were 9/9 at 1 and 5 minutes of life with a birth weight 3.6 kg. Prior to

postpartum discharge, oxygen therapy was discontinued by pulmonology. An oxygen determination study was recommended as an outpatient after discharge. She has not seen pulmonology again in the postpartum period.

## DISCUSSION

There is minimal literature in regard to change of lung function and disease course in child bearing patients with PLCH, but PLCH does not appear to be a contraindication for pregnancy [4, 5]. Both patients challenge the idea that lung function in patients with PLCH worsens during pregnancy, as despite desiring increased oxygen supplementation for comfort, oxygen saturation remained within pregnancy expected values ( $\geq 95\%$ ) for both patients. We were fortunate to have baseline pulmonary function testing on both patients, and reassuring evidence for our first patient that pulmonary function testing (including her FEV<sub>1</sub> and DLCO) was stable over the course of her pregnancy. Physiologic respiratory changes in pregnancy do not seem to alter the course of PLCH, as most of these changes do not affect airway function, such as alter the FEV<sub>1</sub>/FVC ratio or DLCO [6]. This patient presented us with a gentle reminder: when a pregnant patient presents with dyspnea, we need to distinguish between underlying disease (e.g., PLCH) or new, possibly pregnancy related problems (e.g., pulmonary embolus or dyspnea of pregnancy). She highlighted the importance of continued workup and not relying on the diagnosis of PLCH to explain all symptoms patients may have. Significantly, treatment recommendations for pregnant women are not different when compared to non-pregnant adults, with the exception of delaying chemotherapy for these adults until postpartum. Women should be strongly encouraged to limit any type of tobacco use.

Our first case was affected by fetal growth restriction, whereas our second case had an appropriately grown fetus. It is difficult to infer that fetal weight was impacted specifically by PLCH as both patients had moderate to severe persistent asthma, and our first patient had other comorbidities possibly affecting birth weight including current vaping (with nicotine) use, history of drug use and Hepatitis C. Neither patient had complications in previous pregnancies that would contribute to issues in discussed cases. Asthma is a condition for which fetal surveillance is recommended due to severe or poorly controlled asthma being associated with growth restriction and other adverse perinatal outcomes. Both of our patients would have been undergoing serial ultrasound examinations regardless of PLCH diagnosis [7]. However, if we consider PLCH a mirror of asthma, as a chronic lung disease that can impact fetal well-being, oxygenation, and growth, women with this separate disease may also require and benefit from serial ultrasonography and monitoring. Given lack of available evidence, we recommend consultation with a maternal fetal medicine specialist for pregnancies affected by PLCH and fetal surveillance during pregnancy.

Both patients were recommended to deliver by primary cesarean section, as advised by the pulmonary specialists, due to concern for pneumothorax with vaginal delivery. It has been postulated that patients with PLCH are at risk for recurrent pneumothorax, which more commonly happens in younger patients [8]. Given increased intrathoracic pressure with Valsalva and thus increased risk of pneumothorax in patients with PLCH, serious consideration to primary cesarean section may be beneficial. In past studies, only 23.8% women with PLCH were delivered by cesarean section [4]. Both of our patients underwent spinal anesthesia without complication. In light of the risk of pneumothorax, we recommend joint decision making between obstetricians, pulmonologists, and women at risk for this complication.

## CONCLUSION

Overall, there is scant literature and studies evaluating PLCH and its impact on pregnancy or pregnancy's impact on the disease, including the optimal mode of delivery. Our patients present two significant findings: PLCH may affect birth weight and mode of delivery in pregnancy, and pregnancy does not seem to change the course of PLCH. Term delivery with cesarean section is recommended due to risk of pneumothorax. However, we have highlighted that surveillance during pregnancy, both fetal and maternal, and shared decision making may optimize outcomes for mother and baby.

## REFERENCES

1. Vassallo R, Ryu JH. Pulmonary Langerhans' cell histiocytosis. *Clin Chest Med* 2004;25(3):561-71.
2. Sundar KM, Gosselin MV, Chung HL, Cahill BC. Pulmonary Langerhans cell histiocytosis: Emerging concepts in pathobiology, radiology, and clinical evolution of disease. *Chest* 2003;123(5):1673-83.
3. PDQ Pediatric Treatment Editorial Board. Langerhans cell histiocytosis treatment PDQ®: Patient version. In: PDQ Cancer Information Summaries. Bethesda (MD): National Cancer Institute (US); 2002.
4. Radzikowska E, Wiatr E, Franczuk M, Bestry I, Roszkowski-Sliż K. Lung function in pregnancy in Langerhans cell histiocytosis. *Adv Exp Med Biol* 2018;1023:73-83.
5. Tazi A, Marc K, Dominique S, et al. Serial computed tomography and lung function testing in pulmonary Langerhans' cell histiocytosis. *Eur Respir J* 2012;40(4):905-12.
6. Prowse CM, Gaensler EA. Respiratory and acid-base changes during pregnancy. *Anesthesiology* 1965;26:381-92.
7. Dombroski MP, Schatz M, ACOG Committee on Practice Bulletins-Obstetrics. ACOG Practice Bulletin: Clinical management guideline for obstetrician-gynecologists number 90, February 2008: Asthma in pregnancy. *Obstet Gynecol* 2008;111(2 Pt 1):457-64.

8. Radzikowska E, Błasińska-Przerwa K, Wiatr E, Bestry I, Langfort R, Roszkowski-Śliż K. Pneumothorax in patients with pulmonary Langerhans cell histiocytosis. *Lung* 2018;196(6):715–20.

\*\*\*\*\*

### Author Contributions

Ghamar Bitar – Conception of the work, Design of the work, Acquisition of data, Analysis of data, Interpretation of data, Drafting the work, Revising the work critically for important intellectual content, Final approval of the version to be published, Agree to be accountable for all aspects of the work in ensuring that questions related to the accuracy or integrity of any part of the work are appropriately investigated and resolved

Philip Shlossman – Conception of the work, Design of the work, Acquisition of data, Analysis of data, Interpretation of data, Drafting the work, Revising the work critically for important intellectual content, Final approval of the version to be published, Agree to be accountable for all aspects of the work in ensuring that questions related to the accuracy or integrity of any part of the work are appropriately investigated and resolved

### Guarantor of Submission

The corresponding author is the guarantor of submission.

### Source of Support

None.

### Consent Statement

Written informed consent was obtained from the patient for publication of this article.

### Conflict of Interest

Authors declare no conflict of interest.

### Data Availability

All relevant data are within the paper and its Supporting Information files.

### Copyright

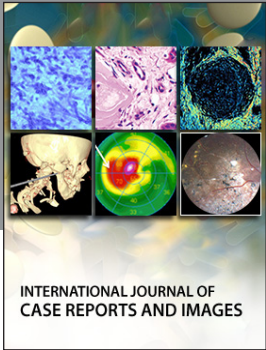
© 2020 Ghamar Bitar et al. This article is distributed under the terms of Creative Commons Attribution License which permits unrestricted use, distribution and reproduction in any medium provided the original author(s) and original publisher are properly credited. Please see the copyright policy on the journal website for more information.

Access full text article on  
other devices



Access PDF of article on  
other devices





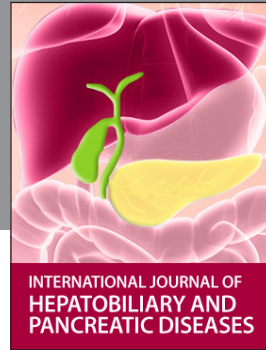INTERNATIONAL JOURNAL OF CASE REPORTS AND IMAGES



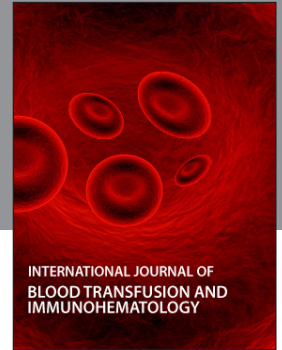VIDEO JOURNAL OF CLINICAL RESEARCH



VIDEO JOURNAL OF BIOMEDICAL SCIENCE



INTERNATIONAL JOURNAL OF HEPATOBILIARY AND PANCREATIC DISEASES



INTERNATIONAL JOURNAL OF BLOOD TRANSFUSION AND IMMUNOHEMATOLOGY



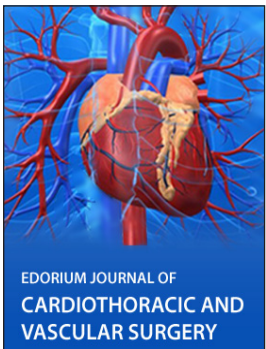
EDORIUM JOURNAL OF OPHTHALMOLOGY



**Submit your manuscripts at**  
[www.edoriumjournals.com](http://www.edoriumjournals.com)



EDORIUM JOURNAL OF MEDICINE



EDORIUM JOURNAL OF CARDIOTHORACIC AND VASCULAR SURGERY



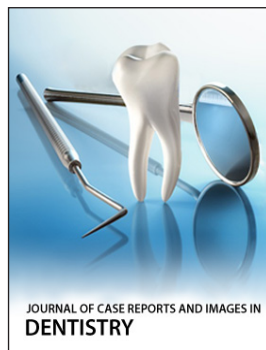
JOURNAL OF CASE REPORTS AND IMAGES IN ORTHOPEDICS AND RHEUMATOLOGY



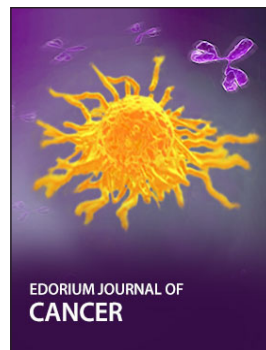EDORIUM JOURNAL OF PSYCHOLOGY




EDORIUM JOURNAL OF CELL BIOLOGY



JOURNAL OF CASE REPORTS AND IMAGES IN DENTISTRY



EDORIUM JOURNAL OF CANCER



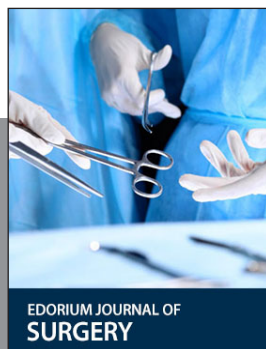EDORIUM JOURNAL OF PSYCHIATRY



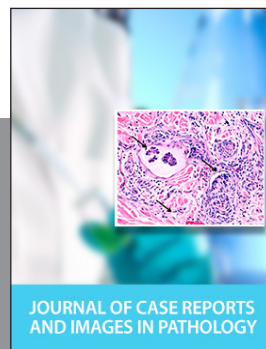JOURNAL OF CASE REPORTS AND IMAGES IN INFECTIOUS DISEASES



EDORIUM JOURNAL OF ANATOMY AND EMBRYOLOGY



EDORIUM JOURNAL OF SURGERY



JOURNAL OF CASE REPORTS AND IMAGES IN PATHOLOGY



EDORIUM JOURNAL OF ANESTHESIA