

# Appendiceal adenocarcinoma: Case report of an unexpected mimicker of ectopic pregnancy

Kristen L Stearns, Sheldon Wasserman

## ABSTRACT

**Introduction:** Appendiceal neoplasms comprise a low percentage of gastrointestinal malignancies. These malignancies are most often noted incidentally on imaging or during surgery. There are few case reports describing malignancy of the appendix during pregnancy and even fewer that involve abnormal pregnancies, such as molar or ectopic pregnancy.

**Case Report:** This is the case of a 32-year-old female who presented with an unknown last menstrual period (LMP), positive home pregnancy test, and right adnexal mass. Due to the concern for ectopic pregnancy, she underwent laparoscopic assessment, revealing an appendiceal neoplasm. She was subsequently diagnosed with a concurrent molar pregnancy.

**Conclusion:** Given the proximity of the appendix to right-sided adnexal structures, appendiceal tumors can be mistaken for ovarian masses, or vice versa. Appendiceal adenocarcinoma often presents with symptoms of acute appendicitis and can mimic the pain of a ruptured ectopic pregnancy in reproductive aged women. Therefore, it is important for clinicians to consider involvement of both structures while evaluating an adnexal mass. Ultrasound imaging is the standard of care for women presenting with pelvic pain and an elevated  $\beta$ -hCG; however, alternative imaging modalities should be considered when ultrasound findings are not definitive.

**Keywords:** Appendiceal neoplasm, Ectopic pregnancy, Hydatidiform mole, Laparoscopic surgery

### How to cite this article

Stearns KL, Wasserman S. Appendiceal adenocarcinoma: Case report of an unexpected mimicker of ectopic pregnancy. J Case Rep Images Obstet Gynecol 2021;7: 100071Z08KS2021.

Article ID: 100071Z08KS2021

\*\*\*\*\*

doi: 10.5348/100071Z08KS2021CR

## INTRODUCTION

Appendiceal neoplasms are rare gastrointestinal malignancies, comprising only 0.5% of intestinal cancers [1]. These tumors are often identified during abdominal surgery or as incidental findings on pelvic imaging [2]. During pregnancy, the incidence of malignant neoplasms is low. While there have been cases of appendiceal malignancies complicating pregnancy, these reports are rare [2–5]. Over half of these cases involve neuroendocrine tumors, which are commonly identified due to their associated carcinoid syndromic presentation [6, 7]. However, many patients with other appendiceal tumors, including adenocarcinomas, present with symptoms of acute appendicitis.

The combination of an adnexal mass, elevated  $\beta$ -hCG, and pelvic pain is highly suspicious for ectopic pregnancy. The concern is particularly high if there is no evidence of an intrauterine pregnancy on ultrasound. The care of these patients greatly depends on the acuity of their clinical presentation. If there is concern for a ruptured ectopic pregnancy, surgical management is recommended, whereas if the patient is stable with low concern for rupture, medical management can be considered. Below, we present the case of a patient with appendiceal adenocarcinoma masquerading as an ectopic pregnancy

Kristen L Stearns<sup>1</sup>, Sheldon Wasserman<sup>2</sup>

**Affiliations:** <sup>1</sup>Resident Physician, Department of Obstetrics and Gynecology, Medical College of Wisconsin, Milwaukee, Wisconsin, USA; <sup>2</sup>Department of Obstetrics and Gynecology, Ascension Medical Group, Milwaukee, Wisconsin, USA.

**Corresponding Author:** Kristen L Stearns, MD, Department of Obstetrics and Gynecology, 9200 W. Wisconsin Ave, Milwaukee, WI 53226, USA; Email: kstearns@mcw.edu

Received: 15 October 2020

Accepted: 16 December 2020

Published: 29 January 2021

in the setting of concurrent, early molar pregnancy. This report reviews relevant literature regarding management of right lower quadrant pain accompanied by an elevated  $\beta$ -hCG.

## CASE REPORT

A 32-year-old gravida 2 para 1 with an uncomplicated past medical history presented to her gynecologist with abdominal pain of two weeks duration and a positive home pregnancy test. She had an unknown LMP and reported this was a highly desired pregnancy.  $\beta$ -hCG was 7,415 mIU/mL. Her vital signs were stable. Bimanual exam revealed a non-enlarged uterus and significant right lower quadrant tenderness to palpation. No cervical motion tenderness or adnexal fullness could be appreciated. There was no transvaginal ultrasound available in the clinic, so the patient was sent to radiology for an ultrasound. Imaging revealed a mildly complex fluid structure within the endometrial cavity without a fetal pole or yolk sac (Figure 1). A complex right adnexal mass, thought to be distinct from the right ovary, was also identified. The patient's provider was contacted directly by the radiology department to report the heterogenous right-sided mass that measured  $3.2 \times 3 \times 5.4$  cm. This was described as "very highly concerning for and most consistent with ectopic pregnancy" (Figure 2). These films were subsequently reviewed by the patient's physician. There was no free fluid noted on imaging and blood flow to the adnexa was appropriate. The report made no specific comments regarding irregularities, septations, papillary projections, or solid components within the mass. Due to ongoing pelvic pain and significant concern for ectopic pregnancy, the patient was counseled on management strategies. Discussion

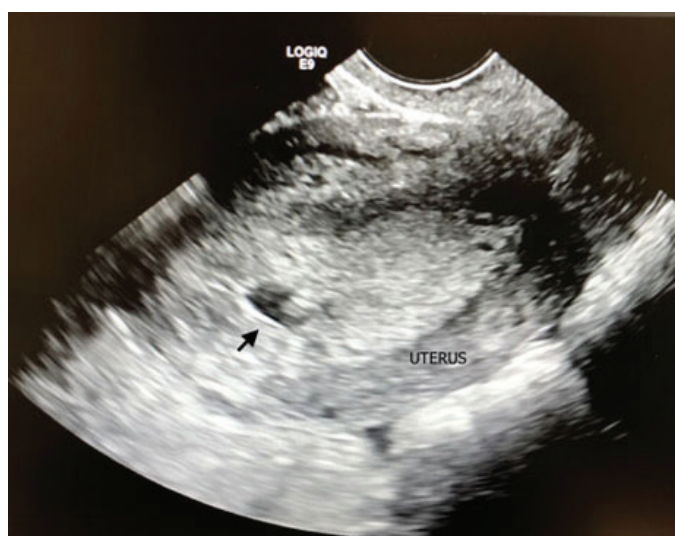

Figure 1: Transvaginal ultrasound of the uterus in the sagittal plane. The black arrow is aimed toward the intrauterine contents. The posterior wall of the uterus is marked "UTERUS."

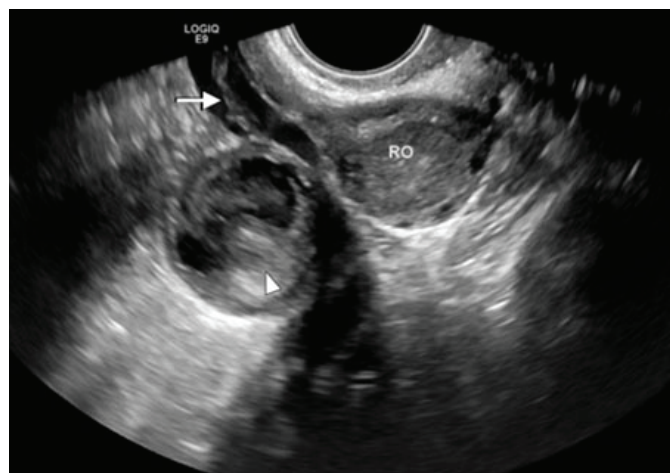


Figure 2: Transvaginal ultrasound of the right adnexa. The right ovary is marked "RO" and the adnexal mass is indicated by the white arrowhead. The iliac vasculature is demonstrated with the white arrow.

included medical management with methotrexate (MTX) and surgical management with laparoscopy. She opted to undergo exploratory laparoscopy to evaluate for ectopic pregnancy and was consented for possible salpingectomy versus salpingostomy.

Intraoperative exploration of the pelvis revealed normal ovaries and fallopian tubes bilaterally. There was no obvious corpus luteum. The uterus was unremarkable. Other pelvic structures were subsequently investigated. The appendix was extensively thickened, firm, and hyperemic with dilation extending proximally to the cecum. General surgery was called to the operative suite and a laparoscopic appendectomy was performed. The remainder of the operation was uncomplicated. Pathology returned as low-grade appendiceal mucinous neoplasm.

$\beta$ -hCG was repeated 48 hours after surgery, and a pelvic ultrasound was performed one week after surgery. The follow-up ultrasound revealed a thickened endometrial lining with numerous small cystic spaces and ill-defined fluid collections, again without a yolk sac or fetal pole.  $\beta$ -hCG at that time had increased further to 108,436 mIU/mL. The findings were suggestive of molar pregnancy and the patient was consented for suction dilation and evacuation. The procedure was performed in the main operating theatre to accommodate for the possibility of excessive bleeding. The uterus was 10-week size and the adnexa was not enlarged on bimanual examination. The procedure was largely uncomplicated and evacuated intrauterine contents were consistent with products of conception. Final pathology revealed a complete hydatidiform mole. Postoperatively, the patient's pain resolved completely.  $\beta$ -hCG was evaluated weekly and trended to zero over. The patient was seen for a postoperative visit three months after surgery and was doing well. She had timely postoperative follow-up with an oncology team. There were no additional

recommendations for surgical or medical management of her appendiceal neoplasm. Chemotherapy and radiation were likewise not recommended. She did not meet criteria for evaluation for metastatic disease with further laboratory workup or imaging.

## DISCUSSION

An ectopic pregnancy should be considered in all young female patients who present with an elevated  $\beta$ -hCG and abdominal pain. However, there are many instances when non-gynecologic and non-obstetric causes of pelvic pain can occur simultaneously with an elevated  $\beta$ -hCG, as demonstrated in this case. The differential diagnosis should include appendicitis, ovarian torsion, endometriosis, and pelvic inflammatory disease, among others diagnoses. However, this case calls for the additional consideration of appendiceal neoplasm for patients presenting with these symptoms.

Primary appendiceal adenocarcinoma is uncommon and is often found incidentally during abdominal or pelvic surgery [2]. In some cases, patients can present with acute appendicitis. Typically, these patients present with right lower quadrant pain, nausea, vomiting, and leukocytosis. Pain at McBurney's point, guarding, and positive obturator and psoas signs are often appreciated. It is important to recognize that pregnancy can distort standard anatomy and alter this presentation. Although rare, this diagnosis must remain on the differential for patients presenting with pelvic pain. Alternatively, ectopic pregnancy is a common diagnosis in women of childbearing age. This diagnosis becomes critical when there is concern for rupture of the ectopic pregnancy. For these patients, surgical management is often necessary to prevent morbidity and mortality. After thorough review of the literature, there is only one report of appendiceal adenocarcinoma mimicking ectopic pregnancy [8]. Our report highlights a case of appendiceal carcinoma in the setting of a molar pregnancy.

Common imaging modalities are imperfect at distinguishing pelvic adnexal structures from gastrointestinal structures. In obstetrics, ultrasound is the most common imaging technique employed to image the pelvis. In our case, the ultrasound demonstrated a separate, complex structure adjacent to the right ovary. While this is a relatively typical sonographic presentation for tubal ectopic pregnancy, the structure had some features that were more consistent with an appendiceal origin. There was no evidence of a gestational sac, yolk sac, or fetal pole within this structure. Also, there was no peripheral blood flow surrounding the structure, which is typical of an ectopic pregnancy [9]. According to Debnath et al., computed tomography (CT) scan or magnetic resonance imaging (MRI) should be considered in cases when ultrasound findings are equivocal [10]. With regard to appendicitis, ultrasound carries an 83% sensitivity, whereas a CT scan is 94% sensitive [11].

Moreover, MRI is frequently employed to image the bowel. While infrequently used during pregnancy, MRI is the preferred method to differentiate pelvic organs from gastrointestinal tract organs and should be considered during pregnancy in select cases [10].

In young women with right lower quadrant pain and an elevated  $\beta$ -hCG, consideration for ectopic pregnancy is paramount. Management of ectopic pregnancy often involves MTX or surgery. While there is not an identified  $\beta$ -hCG level that is an absolute contraindication for MTX treatment, levels greater than 5,000 are associated with a higher failure rate [12, 13]. Additionally, pelvic pain is often associated with a ruptured ectopic mass, and this finding necessitates surgical management [12].

Still, some patients with this presentation may have a gastrointestinal origin for their pain, as appendicitis is relatively common in young women. Appendiceal adenocarcinoma may also present with severe right-sided pelvic pain, though this diagnosis is rare. This possibility can be considered particularly when ultrasound identifies an abnormal structure that is distinct from and adjacent to the ovary. Furthermore, additional imaging modalities should be considered to determine the origin of complex pelvic masses, particularly if ultrasound is not definitive. Additional evaluation with a CT scan or MRI could provide additional cues to assist with delineating between gynecologic structures and gastrointestinal structures, and these imaging studies should be considered in future patients presenting with a similar clinical history.

Another important consideration for future patients presenting with a similar clinical vignette is preoperative ultrasound evaluation and application of the International Ovarian Tumor Analysis (IOTA) Simple Rules. This model is employed to assess adnexal masses and determine likelihood for malignancy. While these rules are intended to be used for ovarian tumors and cannot be likewise applied to gastrointestinal tumors, application can be considered to assist with preoperative determination of malignancy risk in all patients with adnexal masses [14, 15]. The IOTA Simple Rules were not applied in the care of this patient.

Finally, there are certain clinical scenarios when knowledge of patient information could bias the differential diagnosis. This can be true during review of radiologic studies. For example, knowledge of a positive pregnancy test can have an impact on ultrasound review. Therefore, interpretation of imaging studies should be conducted in a manner to promote reduction of bias if safe and possible. A reduction of clinical bias promotes equal and just care for each patient. Finally, pregnancy should always be considered in patients of reproductive age who present with pelvic pain. However, if the clinical or surgical findings do not support a normal pregnancy, attention should be turned to work up for abnormally developing pregnancies, including ectopic and molar pregnancies, as well as assessment for non-gynecologic causes of pelvic pain.

## CONCLUSION

The appendix is closely related to right-sided adnexal structures (i.e., fallopian tube and ovary) such that appendiceal tumors can be incorrectly identified as ovarian masses on physical examination or imaging studies. Therefore, it is important for clinicians to determine which structure is most likely to be involved. While evaluating an adnexal mass in reproductive aged women, careful selection of imaging modalities can assist with diagnosis.

## REFERENCES

1. Sorosky JI, Scott-Conner CE. Breast disease complicating pregnancy. *Obstet Gynecol Clin North Am* 1998;25(2):353–63.
2. Gallo JL, Martínez-Ossa R, Ferrer G, Cámara M. Mucinous appendicular cystadenocarcinoma and pregnancy. *Am J Perinatol* 2001;18(3):155–7.
3. Zeteroglu S, Kotan C, Ozen S, Goktolga U. Mucinous appendicular cystadenocarcinoma during pregnancy. A case report. *J Reprod Med* 2003;48(10):831–3.
4. Morgan DR, Fernandez CO, DeSarno C, Mann WJ Jr. Adenocarcinoma of the appendix in pregnancy: A case report. *J Reprod Med* 2004;49(9):753–5.
5. Chiverto Y, Cabezas E, Pérez-Medina T, Sanfrutos-Llorente L. Infiltrating mucinous appendicular carcinoma during pregnancy. A case report and review of the literature. *J Obstet Gynaecol* 2015;35(8):856–8.
6. Poiana C, Carsote M, Trifanescu R, Terzea D, Croitoru A. Case study of appendiceal carcinoid during pregnancy. *J Med Life* 2012;5(3):325–8.
7. Piatek S, Gajewska M, Panek G, Wielgos M. Carcinoid of the appendix in pregnant woman – Case report and literature review. *Neuro Endocrinol Lett* 2017;37(8):535–9.
8. Thompson RJ, Howe MJG. A rare pathological trinity: An appendiceal ectopic pregnancy, acute appendicitis and a carcinoid tumour. *Ir J Med Sci* 2011;180(2):579–80.
9. Dialani V, Levine D. Ectopic pregnancy: A review. *Ultrasound Q* 2004;20(3):105–17.
10. Debnath J, George RA, Ravikumar R. Imaging in acute appendicitis: What, when, and why? *Med J Armed Forces India* 2017;73(1):74–9.
11. Doria AS, Moineddin R, Kellenberger CJ, et al. US or CT for diagnosis of appendicitis in children and adults? A meta-analysis. *Radiology* 2006;241(1):83–94.
12. American College of Obstetricians and Gynecologists' Committee on Practice Bulletins—Gynecology. ACOG Practice Bulletin No. 193: Tubal ectopic pregnancy. *Obstet Gynecol* 2018;131(3):e91–103.
13. Menon S, Colins J, Barnhart KT. Establishing a human chorionic gonadotropin cutoff to guide methotrexate

treatment of ectopic pregnancy: A systematic review. *Fertil Steril* 2007;87(3):481–4.

14. Timmerman D, Testa AC, Bourne T, et al. Simple ultrasound-based rules for the diagnosis of ovarian cancer. *Ultrasound Obstet Gynecol* 2008;31(6):681–90.
15. American College of Obstetricians and Gynecologists' Committee on Practice Bulletins—Gynecology. Practice Bulletin No. 174: Evaluation and management of adnexal masses. *Obstet Gynecol* 2016;128(5):e210–26.

\*\*\*\*\*

## Author Contributions

Kristen L Stearns – Conception of the work, Design of the work, Drafting the work, Revising the work critically for important intellectual content, Final approval of the version to be published, Agree to be accountable for all aspects of the work in ensuring that questions related to the accuracy or integrity of any part of the work are appropriately investigated and resolved

Sheldon Wasserman – Conception of the work, Revising the work critically for important intellectual content, Final approval of the version to be published, Agree to be accountable for all aspects of the work in ensuring that questions related to the accuracy or integrity of any part of the work are appropriately investigated and resolved

## Guarantor of Submission

The corresponding author is the guarantor of submission.

## Source of Support

None.

## Consent Statement

Written informed consent was obtained from the patient for publication of this article.

## Conflict of Interest

Authors declare no conflict of interest.

## Data Availability


All relevant data are within the paper and its Supporting Information files.

## Copyright


© 2021 Kristen L Stearns et al. This article is distributed under the terms of Creative Commons Attribution License which permits unrestricted use, distribution and reproduction in any medium provided the original author(s) and original publisher are properly credited. Please see the copyright policy on the journal website for more information.

## ABOUT THE AUTHORS

**Article citation:** Stearns KL, Wasserman S. Appendiceal adenocarcinoma: Case report of an unexpected mimicker of ectopic pregnancy. J Case Rep Images Obstet Gynecol 2021;7: 100071Z08KS2021.



**Kristen L Stearns** is a resident physician at the Medical College of Wisconsin in Milwaukee, WI. She earned her undergraduate degree in Molecular and Cellular Biology from the University of Illinois in Champaign-Urbana, IL. She earned her medical degree from the University of Illinois College of Medicine. Her research interests include health disparities in obstetrics and gynecology and developing protocols for enhanced recovery after surgery. She intends to pursue Gynecologic Oncology in the future.



**Sheldon Wasserman**, Department of Obstetrics and Gynecology, Ascension Medical Group, Milwaukee, Wisconsin, USA.

Access full text article on  
other devices



Access PDF of article on  
other devices





INTERNATIONAL JOURNAL OF  
CASE REPORTS AND IMAGES



VIDEO JOURNAL OF  
CLINICAL RESEARCH



VIDEO JOURNAL OF  
BIOMEDICAL SCIENCE



INTERNATIONAL JOURNAL OF  
HEPATOBIILIARY AND  
PANCREATIC DISEASES



INTERNATIONAL JOURNAL OF  
BLOOD TRANSFUSION AND  
IMMUNOHEMATOLOGY



EDORIUM JOURNAL OF  
OPHTHALMOLOGY



**Submit your manuscripts at**  
[www.edoriumjournals.com](http://www.edoriumjournals.com)



EDORIUM JOURNAL OF  
MEDICINE



EDORIUM JOURNAL OF  
CARDIOTHORACIC AND  
VASCULAR SURGERY



JOURNAL OF CASE REPORTS  
AND IMAGES IN ORTHOPEDICS  
AND RHEUMATOLOGY



EDORIUM JOURNAL OF  
PSYCHOLOGY



EDORIUM JOURNAL OF  
CELL BIOLOGY



JOURNAL OF CASE REPORTS AND IMAGES IN  
DENTISTRY



EDORIUM JOURNAL OF  
CANCER



EDORIUM JOURNAL OF  
PSYCHIATRY



JOURNAL OF CASE REPORTS AND  
IMAGES IN INFECTIOUS DISEASES



EDORIUM JOURNAL OF  
ANATOMY AND EMBRYOLOGY



EDORIUM JOURNAL OF  
SURGERY



JOURNAL OF CASE REPORTS  
AND IMAGES IN PATHOLOGY



EDORIUM JOURNAL OF  
ANESTHESIA