

# Fetal acrania: A case report and review of literature

Dilan Malinda Casather, Harsha Atapattu

## ABSTRACT

**Introduction:** Acrania is a lethal congenital malformation characterized by partial or complete absence of flat bones in the cranial vault. In acrania, cerebral hemispheres develop completely and they are abnormal.

**Case Report:** This paper shares a case of fetal acrania in a multiparous woman. Herein, differential diagnosis of fetal cranial abnormalities and their presentations are discussed in the view of the literature.

**Conclusion:** In acrania, prognosis is extremely poor with documented mortality almost 100%. So, an early identification is crucial for the patient counseling and making timely decision about the pregnancy.

**Keywords:** Acalvaria, Acrania, Anencephaly, Encephalocele, Meroacrania

### How to cite this article

Casather DM, Atapattu H. Fetal acrania: A case report and review of literature. J Case Rep Images Obstet Gynecol 2021;7:100077Z08DC2021.

Article ID: 100077Z08DC2021

\*\*\*\*\*

Dilan Malinda Casather<sup>1</sup>, Harsha Atapattu<sup>2</sup>

**Affiliations:** <sup>1</sup>Acting Obstetrician and Gynaecologist, Obstetrics and Gynaecology Unit, Colombo North Teaching Hospital, Ragama, Sri Lanka; <sup>2</sup>Consultant Obstetrician and Gynaecologist, Obstetrics and Gynaecology Unit, De Soysa Hospital for Women, Colombo, Sri Lanka.

**Corresponding Author:** Dr. Dilan Malinda Casather, Colombo North Teaching Hospital, Ragama, Sri Lanka; Email: dilanmalinda7@yahoo.com

Received: 22 February 2021

Accepted: 20 March 2021

Published: 22 April 2021

doi: 10.5348/100077Z08DC2021CR

## INTRODUCTION

Acrania is a congenital malformation with a reported incidence of 1 per 20,000 deliveries [1]. Acrania characterized by partial or complete absence of flat bones in the cranial vault. Even though, cerebral hemispheres develop completely they are abnormal [2]. Acrania occurs as a result of an ectodermal and mesodermal development aberration after neural tube closure [3]. For the diagnosis of the acrania there should be perfectly normal facial bones, a normal vertebral column without fetal skull, and the volume of brain tissue should be equivalent to at least one-third of gestational age matched brain size. Acrania is uniformly lethal entity with limited treatment. However, early detection is extremely important as it allows the clinicians and families to make an appropriate decision about the pregnancy.

## CASE REPORT

A 34-year-old non-diabetic, multiparous woman (G4 P3 C3) was referred for an obstetric ultrasound scan at 14 weeks of gestation. All of whose children are healthy. She had unremarkable medical and obstetric history. The parents were non-consanguineous, and there was no significant family history of congenital anomalies. On, ultrasound scan she was found to have an anencephalic fetus with a soft tissue mass resemble to brain tissue attached to the cranial end of the fetus (Figure 1). She had negative serology testing for toxoplasma and cytomegalovirus, and she was immune to rubella. Following initial counseling she was given routine antenatal care. At 22 weeks of gestation, she had detailed fetal ultrasonography for further evaluation of the fetal anomalies. There was a single live fetus with a complete, well-formed brain including lateral ventricles, sulci, interhemispheric fissure, and brain convolutions. But there was no cranium and the brain was covered with a thin membrane. The brain had normal vascular pattern with the normal circle of Willis on color Doppler scan. Pulsed Doppler waves were also appeared normal. Both orbits were equal in size, shape, and they were placed

symmetrically. Fetal nose, nasolabial folds, and other facial structures were recognized and showed symmetry. The cervical, thoracic, lumbar spine, sacrum appeared normal, and had morphologically normal spinal canal. No obvious masses were seen attached to or arising from the spine. The long bones were appeared normal and femur length was compatible with the period of gestation. The four chamber view of the heart, liver, stomach, and bowels appeared normal and there were no ventral body wall defects. Genito-urinary structures appeared normal. Fetal kidneys were normal position, size, shape, and contour with normal pelvicalyceal system. There was well-distended bladder and a female external genitalia. No other gross abnormalities were detected. There was normal amount of liquor with amniotic fluid index of 13 cm. The placenta was in posterior-fundal location with normal thickness. Umbilical cord appeared normal and had good umbilical Doppler activity. The obstetrics ultrasound scan features were same as at 34 weeks of gestation (Figure 2). The fetal magnetic resonance imaging also confirmed the diagnosis if fetal acrania (Figures 3 and 4). Parents were counseled regarding the condition and the poor prognosis of the baby.

A fully mature baby weighing 2.8 kg was delivered by an emergency lower segment caesarian section due to the transverse lie at the labor at 36 weeks of gestation. The baby cried at birth and did not need initial resuscitation. The Apgar score of the baby was 7 and 9 in 1st and 5th minute, respectively. The baby's brain was displaced posteriorly due to the absence of supporting flat cranial bones (Figure 5). Cranial flat bones were missing from 2 to 3 cm above the ears all around except in the frontal area where it extended upwards in the midline. There were no temporal, parietal, and occipital bones in the fetal skull. The brain was covered by a thin membrane. The well-formed cerebral hemispheres were there. By palpation confirmed the absence of bony calvaria. The oral cavity was appeared normal. The extremities and spine were

normal. Systemic examination was unremarkable. Facial structure and external appearance of rest of the body structures were appeared completely normal. The baby had well-coordinated body movements. On admission, the baby had blue peripheries on room air. Baby's respiration was irregular but, there was no significant cardiac murmur to suggest cardiovascular involvement. The baby was admitted to the neonatal intensive care unit following delivery with a plan of conservative management. The baby developed sudden cardiorespiratory arrest a few hours later and expired. A pathological postmortem was not done as parents did not consent.

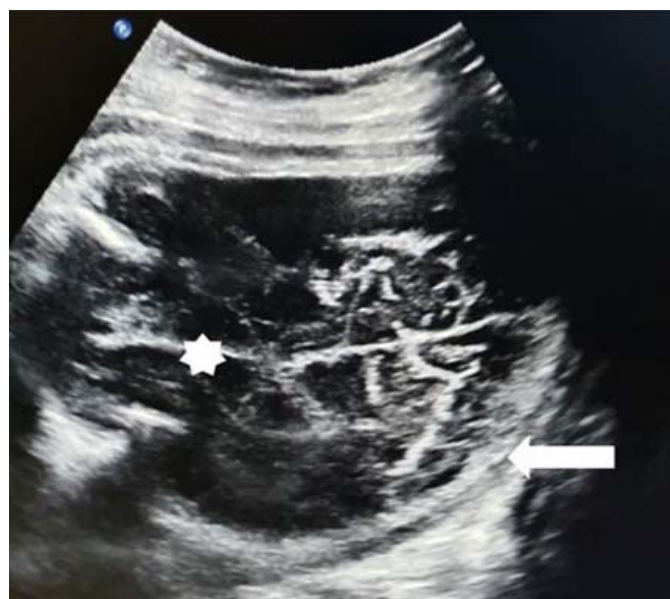

Figure 2: Fetal acrania, gray-scale ultrasound scan of the fetal brain (35 Hz probe) in axial plane, gestational age 34 weeks, no skull around the brain (arrow), asterisk head indicates inter-hemispheric fissure.

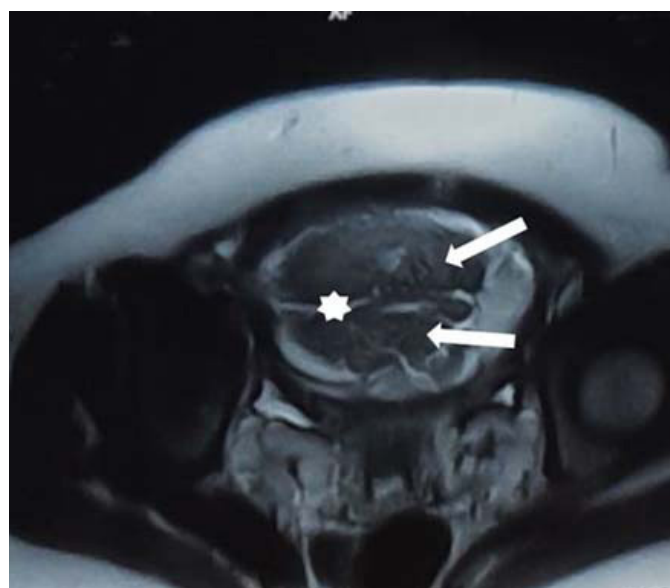


Figure 3: Fetal acrania, fetal MRI in axial plane, gestational age 34 weeks, no skull around the brain, cerebral hemispheres (arrows), asterisk indicates inter-hemispheric fissure.

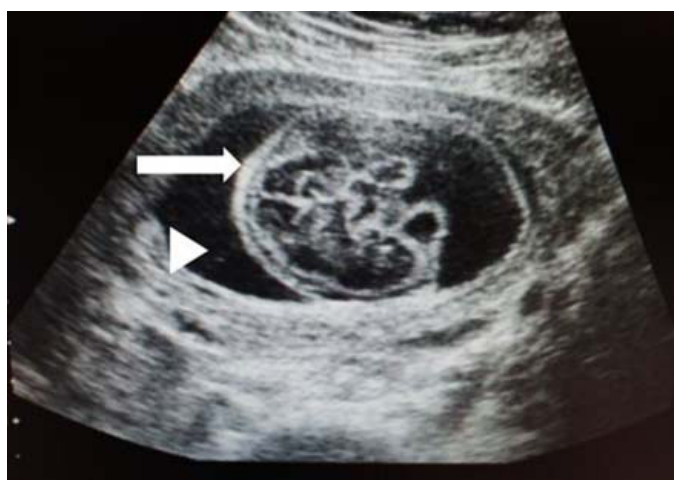

Figure 1: Fetal acrania, gray-scale ultrasound scan of the fetal brain (35 Hz probe) in axial plane, gestational age 14 weeks. No skull around the brain (arrow), arrow head indicates amniotic fluid around the brain.

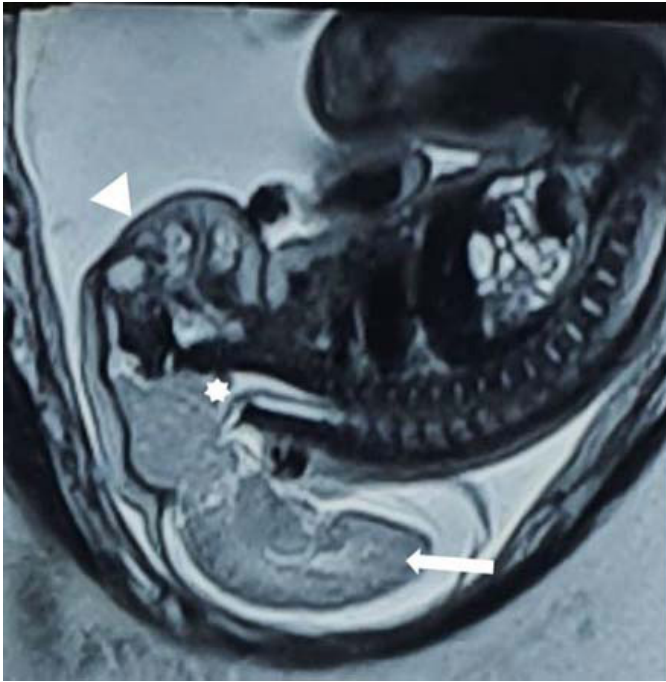


Figure 4: Fetal acrania, fetal MRI in sagittal plane, gestational age 34 weeks, no skull around the brain, cerebral hemisphere (arrow), asterisk indicates the cerebellum. Arrow head indicates the fetal face.

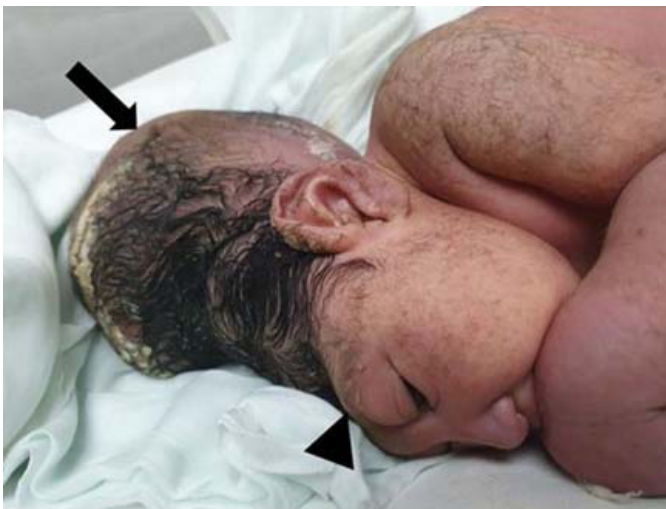

Figure 5: Acrania, demonstrating the absence of cranium with well-developed brain protruding outside the skull base. Arrow indicates fetal brain and arrow head indicates fetal face.

## DISCUSSION

There is no exact mechanism that causes acrania. Like most of the developmental malformations it is hypothesized that there are multiple origins for acrania. Mutations in the hedgehog acyltransferase gene, that disturb production of extracellular kinases, fibroblast growth factors, and bone morphogenic proteins, may responsible for the deformed cranio-fascial patterning [4]. Amniotic band syndrome is another postulated

mechanism that cause fetal acrania [5]. An ectodermal and mesenchymal developmental aberration after the neural tube closure is the main suggested pathology for acrania. There for acrania is considered to be a post-neutralization defect. Mesenchyme is the cell layer that eventually formed the cartilage and bone. When the migration of mesenchyme under the ectoderm does not occur, the skull will not be able to form. The exact cause for the failure of mesenchymal migration is not well understood [3]. The cerebral tissues fail to form two hemisphere, but brainstem, cerebellum, and cranial nerves are normal in fetus with acrania.

The term “acrania” is sometimes confused with encephalocele, anencephaly, and acalvaria. In encephalocele, cranial vault is always detected and part of brain parenchyma protrudes to the outside. While in anencephaly cerebral tissues are completely absent. In meroacrania basis cranii bones (foramen magnum, clivus, and occipital bone) are normal, but other cranial bones are not developed [1]. Acalvaria is the closest differential diagnoses and they have been used synonymously in the medical literature. Compare to the acrania in acalvaria cranial contents is completely covered by the scalp, whereas, in Acrania, brain is exposed to the exterior [6]. Furthermore, acalvaria could be consistent with life, while acrania is essentially lethal. Several authors described an observation called “Acrania–Anencephaly sequence” using sonographic findings of the fetal skull in early pregnancy [7]. According to this, unprotected brain tissues of the acranial fetus undergo destruction due to chemical and mechanical trauma, leading to complete disappearance of the brain tissues at the 14 weeks of gestation, and form an anencephalic fetus. An acrania can be diagnosed as early as 11th week of gestation. Due to the presence of an acrania-anencephaly sequence, the diagnosis of acrania should be made cautiously in the first trimester.

Absence of the skull bones and the presence of brain tissues needed to be there in order to make ultrasound scan diagnosis acrania. The axial and the coronal are the recommended planes should use during the diagnosis of acrania. If mid-sagittal view is obtained defaulted cranial ossification may not be noted as lateral aspect of the frontal bones and lower parietal bones are normal [8]. Fetal magnetic resonance imaging and three-dimensional ultrasound scans further elaborate the diagnosis of fetal acrania.

Severe osteogenesis imperfecta and hypophosphatasia also cause poor mineralization of the cranium and produce ultrasound scan features similar to the acrania [9]. So, differentiation is possible following postnatal examination only. Micropolygyria, facial clefts, and cardiac abnormalities and orbital floor deformities also reported in association with acrania. Even though genetic origin not fully detected, and recurrences rates are extremely low genetic counseling can be offered [10].

## CONCLUSION

In acrania, prognosis is extremely poor with documented mortality almost 100%. So, an early identification is crucial for the patient counseling and making timely decision about the pregnancy.

## REFERENCES

1. Yildirim H, Koç M, Kurt N, Artaş H, Aygün D. Neonate with meroacrania: Radiological findings and review of the literature. *Diagn Interv Radiol* 2009;15(4):232–5.
2. Bianca S, Ingegnosi C, Auditore S, et al. Prenatal and postnatal findings of acrania. *Arch Gynecol Obstet* 2005;271(3):256–8.
3. Mannes EJ, Crelin ES, Hobbins JS, Viscomi GN, Alcebo L. Sonographic demonstration of fetal acrania. *American Journal of Roentgenology* 1982;139(1):181–2.
4. Dennis JF, Kurosaka H, Iulianella A, et al. Mutations in Hedgehog acyltransferase (Hhat) perturb Hedgehog signaling, resulting in severe acrania-holoprosencephaly-agnathia craniofacial defects. *PLoS Genet* 2012;8(10):e1002927.
5. Chandran S, Lim MK, Yu VY. Fetal acalvaria with amniotic band syndrome. *Arch Dis Child Fetal Neonatal Ed* 2000;82(1):F11–3.
6. Johnson SP, Sebire NJ, Snijders RJ, Tunkel S, Nicolaides KH. Ultrasound screening for anencephaly at 10–14 weeks of gestation. *Ultrasound Obstet Gynecol* 1997;9(1):14–6.
7. Bronshtein M, Ornoy A. Acrania: Anencephaly resulting from secondary degeneration of a closed neural tube: Two cases in the same family. *J Clin Ultrasound* 1991;19(4):230–4.
8. Ekici E, Gülmezoglu AM. Sonographic diagnosis of fetal acrania. *J Clin Ultrasound* 1991;19(6):363–6.
9. Amin MU, Mahmood R, Nafees M, Shakoor T. Fetal acrania - prenatal sonographic diagnosis and imaging features of aborted fetal brain. *J Radiol Case Rep* 2009;3(7):27–34.
10. Botto LD, Moore CA, Khoury MJ, Erickson JD. Neural-tube defects. *N Engl J Med* 1999;341(20):1509–19.

\*\*\*\*\*

## Acknowledgments

I would like to thank the patient who participated in this paper for her immense support throughout the study.

## Author Contributions

Dilan Malinda Casather – Conception of the work, Design of the work, Drafting the work, Final approval of the version to be published, Agree to be accountable for all aspects of the work in ensuring that questions related to the accuracy or integrity of any part of the work are appropriately investigated and resolved

Harsha Atapattu – Conception of the work, Drafting the work, Final approval of the version to be published, Agree to be accountable for all aspects of the work in ensuring that questions related to the accuracy or integrity of any part of the work are appropriately investigated and resolved

## Guarantor of Submission

The corresponding author is the guarantor of submission.

## Source of Support

None.

## Consent Statement

Written informed consent was obtained from the patient for publication of this article.

## Conflict of Interest

Authors declare no conflict of interest.

## Data Availability

All relevant data are within the paper and its Supporting Information files.

## Copyright

© 2021 Dilan Malinda Casather et al. This article is distributed under the terms of Creative Commons Attribution License which permits unrestricted use, distribution and reproduction in any medium provided the original author(s) and original publisher are properly credited. Please see the copyright policy on the journal website for more information.

## ABOUT THE AUTHORS

**Article citation:** Casather DM, Atapattu H. Fetal acrania: A case report and review of literature. J Case Rep Images Obstet Gynecol 2021;7:100077Z08DC2021.



**Dilan Malinda Casather** is Acting Obstetrician and Gynaecologist at Colombo North Teaching Hospital, Ragama, Sri Lanka. He earned the Undergraduate Degree MBBS from Faculty of Medicine, University of Kelaniya, Sri Lanka and Postgraduate Degree (MD) in Obstetrics and Gynaecology from Post Graduate Institute of Medicine, University of Colombo, Sri Lanka. His research interests include Fetal Medicine, Benign Gynaecology, and Urogynaecology. He intends to pursue PhD in Obstetrics and Gynaecology in future.

Email: dilanmalinda77@gmail.com



**Harsha Atapattu** is Consultant Obstetrician and Gynaecologist at De Soysa Hospital for Women, Colombo 08, Sri Lanka. He earned the Undergraduate Degree MBBS, from Faculty of Medicine, University of Colombo and Postgraduate Degree (MD) in Obstetrics and Gynaecology from Post Graduate Institute of Medicine, University of Colombo, Sri Lanka.

Access full text article on  
other devices



Access PDF of article on  
other devices





INTERNATIONAL JOURNAL OF  
CASE REPORTS AND IMAGES



VIDEO JOURNAL OF  
CLINICAL RESEARCH



VIDEO JOURNAL OF  
BIOMEDICAL SCIENCE



INTERNATIONAL JOURNAL OF  
HEPATOBIILIARY AND  
PANCREATIC DISEASES



INTERNATIONAL JOURNAL OF  
BLOOD TRANSFUSION AND  
IMMUNOHEMATOLOGY



EDORIUM JOURNAL OF  
OPHTHALMOLOGY



**Submit your manuscripts at**  
[www.edoriumjournals.com](http://www.edoriumjournals.com)



EDORIUM JOURNAL OF  
MEDICINE



EDORIUM JOURNAL OF  
CARDIOTHORACIC AND  
VASCULAR SURGERY



JOURNAL OF CASE REPORTS  
AND IMAGES IN ORTHOPEDICS  
AND RHEUMATOLOGY



EDORIUM JOURNAL OF  
PSYCHOLOGY



EDORIUM JOURNAL OF  
CELL BIOLOGY



JOURNAL OF CASE REPORTS AND IMAGES IN  
DENTISTRY



EDORIUM JOURNAL OF  
CANCER



EDORIUM JOURNAL OF  
PSYCHIATRY



JOURNAL OF CASE REPORTS AND  
IMAGES IN INFECTIOUS DISEASES



EDORIUM JOURNAL OF  
ANATOMY AND EMBRYOLOGY



EDORIUM JOURNAL OF  
SURGERY



JOURNAL OF CASE REPORTS  
AND IMAGES IN PATHOLOGY



EDORIUM JOURNAL OF  
ANESTHESIA