

## CASE REPORT

## PEER REVIEWED | OPEN ACCESS

# Large vulvar hematoma secondary to obturator artery pseudoaneurysm following uncomplicated vaginal delivery: A case report and review of the literature

Paulina J Haight, Miranda Kiefer

## ABSTRACT

**Introduction:** Vulvovaginal hematoma and pseudoaneurysm of the pelvic vasculature are uncommon causes of postpartum hemorrhage. In this report we present the case of an obturator artery branch pseudoaneurysm causing puerperal vulvovaginal hematoma following uncomplicated vaginal delivery.

**Case Report:** We present the case of a 27-year-old multiparous patient who underwent uneventful vaginal birth after cesarean (VBAC) following preterm premature rupture of membranes (PPROM) at 36w4d gestation. Within the immediate postpartum period she developed a rapidly expanding vulvar hematoma, with subsequent acute blood loss anemia and hypotension. Computed tomography (CT) angiogram of the pelvis showed a pseudoaneurysm of a branch of the right obturator artery, and she underwent successful coil embolization with interventional radiology. Incision and drainage was performed the following day with evacuation of the hematoma, and significant improvement in edema and pain.

**Conclusion:** Obturator artery pseudoaneurysm is a rare cause of puerperal vulvovaginal hematoma that has not yet been described in the literature. We propose that CT angiography and arterial embolization should be considered in the setting of rapidly expanding puerperal vulvovaginal hematoma in a stable patient.

Paulina J Haight<sup>1</sup>, MD, Miranda Kiefer<sup>1</sup>, DO

**Affiliation:** <sup>1</sup>Department of Obstetrics and Gynecology, The Ohio State University Wexner Medical Center, Columbus, Ohio, USA.

**Corresponding Author:** Paulina J Haight, Department of Obstetrics and Gynecology, 5th Floor, 395 W. 12th Avenue, Columbus, Ohio 43210, USA; Email: paulina.haight@osumc.edu

Received: 22 February 2021

Accepted: 30 April 2021

Published: 04 June 2021

**Keywords:** Obturator artery pseudoaneurysm, Vulvar hematoma

### How to cite this article

Haight PJ, Kiefer M. Large vulvar hematoma secondary to obturator artery pseudoaneurysm following uncomplicated vaginal delivery: A case report and review of the literature. J Case Rep Images Obstet Gynecol 2021;7: 100079Z08PH2021.

Article ID: 100079Z08PH2021

\*\*\*\*\*

doi: 10.5348/100079Z08PH2021CR

## INTRODUCTION

Postpartum hemorrhage is a significant cause of maternal morbidity in the United States, and the leading cause of maternal mortality worldwide. The most common causes of primary postpartum hemorrhage include uterine atony, laceration, retained placenta or maternal bleeding disorder [1]. Less commonly, vulvovaginal hematoma and pseudoaneurysm of the pelvic vasculature can cause postpartum hemorrhage.

Puerperal hematoma is a rare but serious obstetrical complication that occurs in 1 in 300–1500 deliveries [2]. Risk factors for the development of postpartum vulvovaginal hematomas include laceration, episiotomy, operative delivery, nulliparity, macrosomia, increasing maternal age and maternal coagulation abnormalities [2–4]. Vulvovaginal hematomas result from lacerated vessels in the superficial fascia of the anterior or posterior pelvic triangle. Size is restricted by Colles fascia, the urogenital diaphragm and anal fascia. The mass extends toward the skin as bleeding continues and can theoretically result in rupture or skin necrosis [4, 5]. Alternatively, if the

hematoma originates or extends into the upper vagina, it may track into the retroperitoneal space and cause massive, unrestricted hemorrhage [6]. Fortunately, most hematomas form due to slow venous oozing and do not often result in life-threatening bleeding [4, 7]. Puerperal hematoma formation from arterial bleeding, or even an arterial pseudoaneurysm, is more rare and can lead to catastrophic hemorrhage [8].

Pseudoaneurysm refers to a disruption in the arterial wall caused by inflammation or trauma. Rupture of a pseudoaneurysm can lead to life-threatening bleeding [9, 10]. Pelvic artery pseudoaneurysms cause 3.3% of secondary postpartum hemorrhage (within 24 hours to 6 weeks post-delivery), but they are a rare cause of immediate postpartum hemorrhage (onset <24 hours). The majority of postpartum pseudoaneurysms (75%) are diagnosed within the uterine artery and lead to significant uterine bleeding [8]. There are rare reports of pseudoaneurysm rupture in alternate locations following obstetric delivery, including the vaginal artery, internal pudendal artery, and labial artery [9–11]. In each case, angiography and selective arterial embolization were used to successfully achieve cessation of postpartum hemorrhage.

Management of puerperal hematoma is dependent on the patient’s clinical status and may include a combination of conservative measures, transfusion, surgical evacuation, and/or arterial embolization [1]. When vulvovaginal hematoma and postpartum hemorrhage result from arterial pseudoaneurysm rupture, we advocate for selective arterial embolization, followed by surgical evacuation especially when the hematoma is large in order to avoid prolonged pain and skin necrosis.

**CASE REPORT**

The patient is a 27-year-old multiparous woman (G2P0101) who presented to labor and delivery triage at 36 weeks and 4 days gestation with complaint of leakage of fluid and was found to have preterm premature rupture of membranes (PPROM). Her obstetric history was significant for a prior cesarean delivery due to fetal malpresentation. She strongly desired trial of labor after cesarean delivery and was admitted for augmentation of labor following presentation and PPRM. Induction agents included an intracervical Foley catheter and intravenous (IV) Pitocin. The patient was diagnosed with preeclampsia with severe features during her intrapartum course and was started on IV magnesium for seizure prophylaxis. She did not have history of bleeding disorder. Otherwise, her labor progressed well, and she underwent an uncomplicated, non-operative vaginal birth after cesarean delivery of a live-born male infant weighing 2240 g. No episiotomy was made. A hemostatic and superficial 3 cm laceration involving only the vaginal mucosa just to the right of midline was repaired in standard running locked fashion.

Immediately postpartum at the time of the patient’s laceration repair, she developed a right labial hematoma

which was initially small and stable at 2 cm. Within the course of 1 hour, it began to expand until it reached 10 cm in the greatest dimension over the course of 4 hours (Figure 1A and B). As the hematoma expanded, the patient reported perineal pain in addition to light-headedness. She became hemodynamically unstable due to hypotension and acute blood loss anemia, with hemoglobin drop from 9.7 to a nadir of 6.5 within several hours of delivery as the hematoma expanded. Hypotension resolved with fluid resuscitation and transfusion of 2 units of packed red blood cells. Due to rapid expansion of the hematoma a CT angiogram was performed which demonstrated a pseudoaneurysm with active bleeding from a branch of the right obturator artery. Interventional radiology performed a successful coil embolization of the distal right obturator artery branch which supplied the pseudoaneurysm (Figure 2A and B). Following the procedure, hematoma size and hemodynamic status remained stable. The next day, the patient was recommended to undergo subsequent incision and drainage given large hematoma size and concern for tissue compression and possible necrosis. She underwent uncomplicated incision and drainage with evacuation of the hematoma, with estimated blood loss 300 mL. No active bleeding was noted following the procedure and the

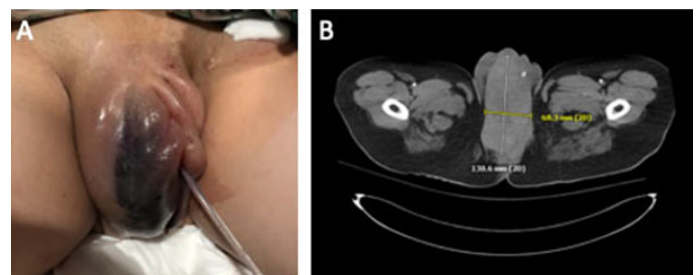


Figure 1: Rapidly expanding puerperal hematoma. (A) Clinical photograph of right labial hematoma with Foley catheter in place. (B) Transverse section CT of the pelvis confirms large vulvovaginal hematoma.

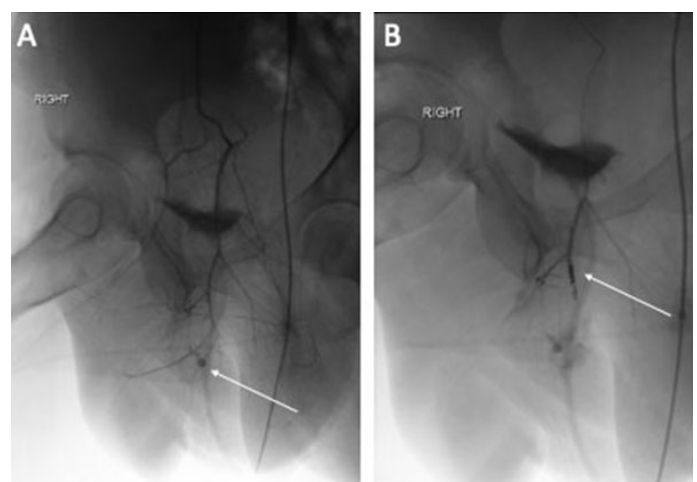


Figure 2: CT angiography. (A) Pseudoaneurysm (arrow) with active bleed from the branches of the right obturator artery. (B) Coil embolization (arrow) of the distal right obturator artery branches that supply the pseudoaneurysm.

vagina was packed. The patient did receive 24 hours of Ancef in the perioperative period for infection prophylaxis, after which time antibiotics were discontinued. Packing was removed on postoperative day 1 with significant improvement noted in labial edema. She was discharged to home on postpartum day 3 (postoperative day 2) and was doing well at the time of her 6-week postpartum follow-up appointment.

## DISCUSSION

This case highlights both vulvovaginal hematoma and pelvic artery pseudoaneurysm as rare but life-threatening causes of postpartum hemorrhage. Puerperal hematomas typically develop following a vaginal delivery complicated by the need for operative instrumentation, laceration, or macrosomia. Most vulvovaginal hematomas are small and resolve with conservative measures alone, although few require surgical intervention. Pelvic artery pseudoaneurysm, another unique obstetrical complication, typically arises from the uterine artery and presents as secondary postpartum hemorrhage due to heavy uterine bleeding [8, 11]. Rarely does a pseudoaneurysm of the pelvic vasculature cause a rapidly expanding vulvovaginal hematoma in the immediate postpartum period.

It is our understanding that there are only three other reports describing a postpartum pelvic artery pseudoaneurysm arising from a source that is not the uterine artery [9–11]. These included pseudoaneurysms of the labial artery, vaginal artery, and internal pudendal arteries. All of these resulted in secondary postpartum hemorrhage, with pseudoaneurysm of the pelvic vasculature diagnosed by CT angiography. Each case presented as massive hemorrhage, and was successfully managed with selective arterial embolization, and there were no reports of subsequent vaginal or vulvar necrosis following embolization.

While we can certainly draw conclusions from the above reports, to the best of our knowledge no case of obturator artery pseudoaneurysm resulting in significant puerperal hematoma has been reported. This is especially interesting in the setting of relatively uncomplicated vaginal delivery with no risk factors for hematoma formation.

Generally speaking, the management of puerperal hematoma is multifactorial. Per the American College of Obstetricians and Gynecologists (ACOG), most genital tract hematomas can be managed conservatively with blood product transfusion as needed. However, in the case of a hematoma that is rapidly expanding, or vital sign instability, surgical evacuation is recommended [1]. Unfortunately, when surgical management is pursued the tamponade against the bleeding vessel is often released, and bleeding continues until the vessel can be discovered and ligated [6]. American College of Obstetricians and Gynecologists also offers selective arterial embolization as an option; however, the criteria for its utilization are unclear.

Surgical evacuation of puerperal hematoma was the mainstay of treatment until around 1980, when reports of selective arterial embolization started to arise [2]. However, determining one route of management versus the other can be challenging. Tsumagari et al. created an algorithm for management of puerperal hematoma, stating that location should determine treatment. Vulvovaginal hematomas should be observed versus surgically evacuated, whereas upper vaginal hematomas should undergo CT angiography for assessment of selective arterial embolization [2].

We feel that this algorithm is not a “one size fits all” approach. In our case, the patient developed rapidly expanding hematoma over the course of several hours immediately postpartum. She experienced acute blood loss anemia requiring transfusion and vital sign instability. Given the overall clinical picture our cohort was concerned for an arterial bleed, which is why CT angiography was performed and interventional radiology was consulted. Following embolization of the right obturator artery branch pseudoaneurysm, the patient’s hematoma size and hemodynamic status remained stable. This allowed for our team to pursue controlled hematoma evacuation, which may have decreased the risk of skin breakdown and necrosis. The patient is currently doing well at time of last follow-up with significant improvement in vulvar edema and pain. The combination approach of transfusion, selective arterial embolization, and surgical evacuation was successful in our case, and we would recommend such approach if clinical suspicion of arterial bleeding is high.

## CONCLUSION

Obturator artery pseudoaneurysm is a rare cause of puerperal vulvovaginal hematoma that has not yet been described in the literature. We argue that CT angiography and arterial embolization should be considered in the setting of rapidly expanding puerperal vulvovaginal hematoma.

## REFERENCES

1. Committee on Practice Bulletins-Obstetrics. Practice Bulletin No. 183: Postpartum Hemorrhage. *Obstet Gynecol* 2017;130(4):e168–86.
2. Tsumagari A, Ohara R, Mayumi M, et al. Clinical characteristics, treatment indications and treatment algorithm for post-partum hematomas. *J Obstet Gynaecol Res* 2019;45(6):1127–33.
3. Saleem Z, Rydhström H. Vaginal hematoma during parturition: A population-based study. *Acta Obstet Gynecol Scand* 2004;83(6):560–2.
4. Gentric JC, Koch G, Lesoeur M, Hebert T, Nonent M. Diagnosis and management of puerperal hematomas: Two cases. *Cardiovasc Intervent Radiol* 2013;36(4):1174–6.
5. Francois KE, Foley MR. Antepartum and Postpartum Hemorrhage. In: Landon MB, Galan HL, Jauniaux ERM, et al. editors. *Gabbe’s Obstetrics: Normal and*

- Problem Pregnancies. 8ed. Philadelphia: Elsevier; 2021. p.359–65.
6. Takagi K, Akashi K, Horiuchi I, et al. Managing vulvovaginal hematoma by arterial embolization as first-line hemostatic therapy. *Taiwan J Obstet Gynecol* 2017;56(2):224–6.
  7. Tseng JY, Lin IC, Lin JH, Chang CM, Chao WT, Wang PH. Optimal approach for management of postpartum vulva hematoma: Report of three cases. *Taiwan J Obstet Gynecol* 2020;59(5):780–3.
  8. Dohan A, Soyer P, Subhani A, et al. Postpartum hemorrhage resulting from pelvic pseudoaneurysm: A retrospective analysis of 588 consecutive cases treated by arterial embolization. *Cardiovasc Intervent Radiol* 2013;36(5):1247–55.
  9. Gondo S, Urushiyama D, Yoshizato T, et al. The successful detection of postpartum unruptured vaginal pseudoaneurysm using ultrasonography: A case report. *Springerplus* 2014;3:482.
  10. Nagayama C, Gibo M, Nitta H, et al. Rupture of pseudoaneurysm after vaginal delivery successfully treated by selective arterial embolization. *Arch Gynecol Obstet* 2011;283(1):37–40.
  11. Leaf MC, Schmidt L, Serna-Gallegos T, Lane F. A ruptured vulvar labial artery pseudoaneurysm causes a secondary postpartum hemorrhage: A case report. *Case Reports in Women’s Health* 2020;26:e00184.

\*\*\*\*\*

**Acknowledgments**

Kara Rood MD, Maged Costantine MD, and Patrick Schneider MD

**Author Contributions**

Paulina J Haight – Conception of the work, Design of the work, Acquisition of data, Analysis of data, Interpretation of data, Drafting the work, Revising the work critically for important intellectual content, Final approval of the

version to be published, Agree to be accountable for all aspects of the work in ensuring that questions related to the accuracy or integrity of any part of the work are appropriately investigated and resolved

Miranda Kiefer – Conception of the work, Revising the work critically for important intellectual content, Final approval of the version to be published, Agree to be accountable for all aspects of the work in ensuring that questions related to the accuracy or integrity of any part of the work are appropriately investigated and resolved

**Guarantor of Submission**

The corresponding author is the guarantor of submission.

**Source of Support**

None.

**Consent Statement**

Written informed consent was obtained from the patient for publication of this article.

**Conflict of Interest**

Authors declare no conflict of interest.

**Data Availability**

All relevant data are within the paper and its Supporting Information files.

**Copyright**

© 2021 Paulina J Haight et al. This article is distributed under the terms of Creative Commons Attribution License which permits unrestricted use, distribution and reproduction in any medium provided the original author(s) and original publisher are properly credited. Please see the copyright policy on the journal website for more information.

Access full text article on other devices



Access PDF of article on other devices





INTERNATIONAL JOURNAL OF  
CASE REPORTS AND IMAGES



VIDEO JOURNAL OF  
CLINICAL RESEARCH



VIDEO JOURNAL OF  
BIOMEDICAL SCIENCE



INTERNATIONAL JOURNAL OF  
HEPATOBIILIARY AND  
PANCREATIC DISEASES



INTERNATIONAL JOURNAL OF  
BLOOD TRANSFUSION AND  
IMMUNOHEMATOLOGY



EDORIUM JOURNAL OF  
OPHTHALMOLOGY



**Submit your manuscripts at**  
[www.edoriumjournals.com](http://www.edoriumjournals.com)



EDORIUM JOURNAL OF  
MEDICINE



EDORIUM JOURNAL OF  
CARDIOTHORACIC AND  
VASCULAR SURGERY



JOURNAL OF CASE REPORTS  
AND IMAGES IN ORTHOPEDICS  
AND RHEUMATOLOGY



EDORIUM JOURNAL OF  
PSYCHOLOGY



EDORIUM JOURNAL OF  
CELL BIOLOGY



JOURNAL OF CASE REPORTS AND IMAGES IN  
DENTISTRY



EDORIUM JOURNAL OF  
CANCER



EDORIUM JOURNAL OF  
PSYCHIATRY



JOURNAL OF CASE REPORTS AND  
IMAGES IN INFECTIOUS DISEASES



EDORIUM JOURNAL OF  
ANATOMY AND EMBRYOLOGY



EDORIUM JOURNAL OF  
SURGERY



JOURNAL OF CASE REPORTS  
AND IMAGES IN PATHOLOGY



EDORIUM JOURNAL OF  
ANESTHESIA