

Transient renal tubular acidosis presenting with rhabdomyolysis in pregnancy: A case report

Margaret M Seybolt, Ronald Thomas, Sohaib Zahid

ABSTRACT

Introduction: Several case reports exist suggesting a possible new transient renal tubular acidosis arising in pregnancy as well as a tendency toward rhabdomyolysis in these patients.

Case Report: The case presents a patient with new onset/possibly transient hypokalemia in pregnancy present with symptomatic rhabdomyolysis. The patient was treated with aggressive potassium repletion during pregnancy and weaned off all therapy postpartum.

Conclusion: A wide differential allowed for identification of a treatable disease entity with good maternal and fetal/neonatal outcome.

Keywords: Hypokalemia, Pregnancy, Rhabdomyolysis, Renal tubular acidosis

How to cite this article

Seybolt MM, Thomas R, Zahid S. Transient renal tubular acidosis presenting with rhabdomyolysis in pregnancy: A case report. J Case Rep Images Obstet Gynecol 2021;7:100083Z08MS2021.

Margaret M Seybolt¹, Ronald Thomas², Sohaib Zahid³

Affiliations: ¹Department of Obstetrics and Gynecology, West Penn Hospital/Allegheny Health Network, Pittsburgh, Pennsylvania, USA; ²Division of Maternal Fetal Medicine, West Penn Hospital/Allegheny Health Network, Pittsburgh, Pennsylvania, USA; ³Department of Nephrology, Allegheny General Hospital/Allegheny Health Network, Pittsburgh, Pennsylvania, USA.

Corresponding Author: Margaret M Seybolt, Department of Obstetrics and Gynecology, West Penn Hospital, 4800 Friendship Avenue, Tower 5W, Pittsburgh, Pennsylvania 15224, USA; Email: Margaret.seybolt@ahn.org

Received: 08 October 2020

Accepted: 18 February 2021

Published: 07 July 2021

Article ID: 100083Z08MS2021

doi: 10.5348/100083Z08MS2021CR

INTRODUCTION

Rhabdomyolysis represents a rare complication of a relatively common electrolyte abnormality, hypokalemia, usually resulting from profound potassium losses such as occurs in hyperemesis, chronic emesis from other etiologies, diabetic ketoacidosis, prolonged diarrhea, and distal renal tubular acidosis (RTA). Distal RTA is a rare disease with one report putting the total incidence of cases in the United States at 20,000 with the majority being associated with autoimmune disorders, genetic, or drug induced [1]. Several case reports suggest a possible predisposition to this type of rhabdomyolysis and a novel diagnosis of distal RTA in pregnancy [2–4]. Our case presents a previously healthy pregnant patient presenting with rhabdomyolysis due to severe hypokalemia of unknown etiology.

CASE REPORT

A 36-year-old African American female gravida 4, para 2012 at 30 weeks gestation presented with lower extremity pain and weakness that had been going on for the past week. Her current pregnancy and her two prior pregnancies had been uncomplicated. She had previously been delivered of two full term neonates by primary C-section and repeat C-section due to a prior myomectomy. She had had one prior early spontaneous pregnancy loss (second pregnancy). The patient's transport to our facility was from a community hospital emergency department. She had previously been seen at a different community hospital emergency department and been advised that her symptoms were manifestations of a normal pregnancy. On both occasions, the patient complained of profound diffuse weakness. At her second

presentation, she was unable to rise from sitting due to weakness of her bilateral lower extremities. She denied fever, chills, dermatologic complaints, substance use, or new medication exposures. She reported nausea, poor oral intake, and occasional vomiting throughout her pregnancy with a documented 15 kilogram weight loss since the beginning of the pregnancy. She did not have any accompanying symptoms such as polydipsia, polyuria, or hematuria. She denied personal or family history of autoimmune, renal, or metabolic diseases.

At presentation the patient was afebrile, mildly tachycardic, and normotensive. Physical exam was notable for 4/5 strength in the lower extremities bilaterally. Dermatologic exam was unremarkable. Fetal monitoring demonstrated a category I strip. Initial labs were notable for significant hypokalemia (2.1 mEq/L), transaminitis [aspartate aminotransferase (AST) 138 U/L, alanine aminotransferase (ALT) 104 U/L], elevation of creatine kinase (CK) to 6776 U/L (with negative CK-MB and troponin), and metabolic acidosis – anion gap (18 mEq/L). Her thyroid function tests, electrocardiogram (EKG) and a complete blood count were unremarkable. Remainder of labs were also normal, including blood sugar 117, sodium 136, chloride 96, blood urea nitrogen (BUN) 3, Cr 0.6, calcium 9, and magnesium 1.9. Right upper quadrant and renal ultrasounds were both normal as were lower extremities. Doppler studies ruled out deep vein thrombosis as etiology of her lower extremity pain and weakness. The CK level continued to rise over the next 24 hours (peak 8550 U/L) and the patient continued to demonstrate a metabolic acidosis with the bicarbonate dropping to 17 (normal in the third trimester of pregnancy being 20–24 mmol/L). Initial concern was for an atypical hyperemesis gravidarum as the etiology for severe hypokalemia. Despite receiving both intravenous (IV) and PO repletion of potassium over the next several days, the hypokalemia remained unresolved. Urine studies were performed showing inappropriate potassium levels (of 44 mEq/L, normal 15–30 during a hypokalemic state) with a low osmolality gap and a pH of 7.0 consistent with an inability to preserve potassium and appropriately acidify the urine. Urine sodium and chloride were <20 (lowest range available per hospital lab), glucose was negative, protein was 1+ (3.5 mg/dL) with myoglobin level >12 mmol/L. Steroids which had been started in treatment of possible hyperemesis were stopped. Supplemental and maintenance potassium were continued.

The data suggested distal renal tubular acidosis as the etiology of hypokalemia. Given this as a new diagnosis in a patient with a history of prior uncomplicated surgeries and pregnancies, a workup was initiated to search for a cause for a new onset RTA. An autoimmune workup included anti-dsDNA, rheumatoid factor, anti-CCP (anti-cyclic citrullinated peptides), SS-A, and SS-B; all were negative.

Improvement was seen over the next several days and potassium was maintained within acceptable range (3.1–3.8 mEq/L). The CK level trended down to 1663 U/L by the day of discharge. At the time of discharge the patient was

receiving 140 mEq of potassium supplementation daily in addition to a high potassium diet. On follow-up, the only complaint was of continued mild soreness and weakness of the lower extremities.

Electrolyte levels (potassium) continued to be followed. Potassium supplementation was titrated upwards to 240 mEq daily at the time of delivery at 39 weeks gestation. Delivery was via scheduled repeat C-section at 39 weeks. General anesthesia was necessary due to an inability to obtain adequate regional analgesia/anesthesia. Surgery was otherwise uncomplicated. There was note of a uterine window at the site of the prior C-section scar. Apgar scores were 7 and 9 at 1 and 5 minutes, respectively, and the neonate weighed 6 pounds, 10 ounces. The patient reported some subjective lower extremity weakness postpartum and potassium supplements were restarted. Potassium levels drawn at 8 and 14 days postpartum demonstrated normal potassium levels. Potassium supplementation has been titrated downward to 40 mEq daily. Long-term monitoring was planned.

DISCUSSION

Normal physiology of pregnancy includes mild respiratory alkalosis and hyper-filtration by the kidneys explained by increased blood volume and resultant increased urinary loss of electrolytes. These changes are well tolerated compensations that allow for normal fetal oxygenation and acid-base status. Distal (type I) RTA is the most common form of RTA in the western world and occurs as a result of failure of bicarbonate resorption in the collecting duct resulting in inability of the kidneys to acidify the urine or decrease ammonium excretion. Fetal and maternal morbidity and mortality may occur with disruption of normal electrolyte balance in pregnant women with known RTA. Maternal complications of RTA include loss of bone density, hypercalciuria with secondary hyperparathyroidism, and hypokalemia with metabolic acidosis [4–6]. Severe hypokalemia such as manifested in our patient may result in muscle weakness, rhabdomyolysis, and even cardiac arrest. Fetal effects of persistent maternal acidosis can include decreased uterine blood flow with fetal acidosis and long-term intrauterine growth restriction. In contrast, patients with RTA who are adequately monitored and treated during pregnancy tend to do well and have normal birth outcomes with no detrimental effects on fetal/neonatal wellbeing.

Most previous reports of new cases of RTA recognized in adulthood (with or without pregnancy) are related to an associated risk factor such as substance use, autoimmune disease, or other preexisting condition. It is now recognized that RTA may occur as a new diagnosis of transient RTA in an otherwise healthy pregnant patient.

Rhabdomyolysis represents a potentially life-threatening complication of severe hypokalemia regardless of etiology. Potassium release from muscles is decreased due to overall profound hypokalemia ($K < 2.5$ mEq/L)

causing a decrease in vasodilation with poor overall blood flow to muscles, especially during exertion [2–9].

CONCLUSION

A literature review reveals several cases with similar presentations. Though overall generalizability of this case and others is limited by the heterogeneity of presentations, these cases underscore the importance of a broad differential in evaluation of a pregnant patient with an unusual presentation (weakness and rhabdomyolysis) including the consideration of new RTA. With adequate treatment and avoidance of medications that might potentially worsen hypokalemia, maternal and fetal/neonatal morbidity and mortality may be avoided.

REFERENCES

1. Renal Tubular Acidosis – Market Insight, Epidemiology, and Market Forecast – 2030. Drug Pipelines 2021.
2. Carminati G, Chena A, Orlando JM, Russo S, Salomón S, Carena JA. Distal renal tubular acidosis with rhabdomyolysis as the presenting form in 4 pregnant women. [Article in Spanish]. *Nefrologia* 2001;21(2):204–8.
3. Muthukrishnan J, Harikumar K, Jha R, Modi K. Pregnancy predisposes to rhabdomyolysis due to hypokalemia. *Saudi J Kidney Dis Transpl* 2010;21(6):1127–8.
4. Srisuttayasathien M. Hypokalemia-induced rhabdomyolysis as a result of distal renal tubular acidosis in a pregnant woman: A case report and literature review. *Case Rep Obstet Gynecol* 2015;2015:947617.
5. Firmin CJ, Kruger TF, Davids R. Proximal renal tubular acidosis in pregnancy. A case report and literature review. *Gynecol Obstet Invest* 2007;63(6):39–44.
6. Hardardottir H, Lahiri T, Egan JF. Renal tubular acidosis in pregnancy: Case report and literature review. *J Matern Fetal Med* 1997;6(1):16–20.
7. Abbassi-Ghanavati M, Greer LG, Cunningham FG. Pregnancy and laboratory studies: A reference table for clinicians. *Obstet Gynecol* 2009;114(6):1326–31.
8. Seoud M, Adra A, Khalil A, Skaff R, Usta I, Salti I. Transient renal tubular acidosis in pregnancy. *Am J Perinatol* 2000;17(5):249–52.
9. Narcisse D, Agarwal M, Kumar A. A rare case of transient proximal renal tubular acidosis in pregnancy. *Case Rep Nephrol* 2017;2017:1342135.

Author Contributions

Margaret M Seybolt – Conception of the work, Design of the work, Acquisition of data, Analysis of data, Interpretation of data, Drafting the work, Revising the work critically for important intellectual content, Final approval of the version to be published, Agree to be accountable for all aspects of the work in ensuring that questions related to the accuracy or integrity of any part of the work are appropriately investigated and resolved

Ronald Thomas – Conception of the work, Design of the work, Analysis of data, Interpretation of data, Drafting the work, Revising the work critically for important intellectual content, Final approval of the version to be published, Agree to be accountable for all aspects of the work in ensuring that questions related to the accuracy or integrity of any part of the work are appropriately investigated and resolved

Sohaib Zahid – Analysis of data, Interpretation of data, Revising the work critically for important intellectual content, Final approval of the version to be published, Agree to be accountable for all aspects of the work in ensuring that questions related to the accuracy or integrity of any part of the work are appropriately investigated and resolved

Guarantor of Submission

The corresponding author is the guarantor of submission.

Source of Support

None.

Consent Statement

Written informed consent was obtained from the patient for publication of this article.

Conflict of Interest

Authors declare no conflict of interest.

Data Availability

All relevant data are within the paper and its Supporting Information files.

Copyright


© 2021 Margaret M Seybolt et al. This article is distributed under the terms of Creative Commons Attribution License which permits unrestricted use, distribution and reproduction in any medium provided the original author(s) and original publisher are properly credited. Please see the copyright policy on the journal website for more information.

Access full text article on
other devices



Access PDF of article on
other devices





INTERNATIONAL JOURNAL OF
CASE REPORTS AND IMAGES



VIDEO JOURNAL OF
CLINICAL RESEARCH



VIDEO JOURNAL OF
BIOMEDICAL SCIENCE



INTERNATIONAL JOURNAL OF
HEPATOBIILIARY AND
PANCREATIC DISEASES



INTERNATIONAL JOURNAL OF
BLOOD TRANSFUSION AND
IMMUNOHEMATOLOGY



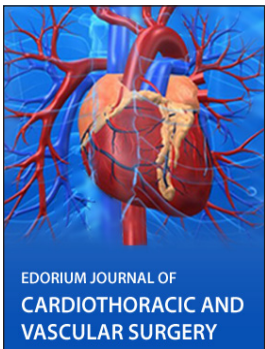
EDORIUM JOURNAL OF
OPHTHALMOLOGY



Submit your manuscripts at
www.edoriumjournals.com



EDORIUM JOURNAL OF
MEDICINE



EDORIUM JOURNAL OF
CARDIOTHORACIC AND
VASCULAR SURGERY



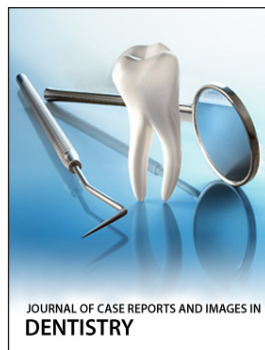
JOURNAL OF CASE REPORTS
AND IMAGES IN ORTHOPEDICS
AND RHEUMATOLOGY



EDORIUM JOURNAL OF
PSYCHOLOGY




EDORIUM JOURNAL OF
CELL BIOLOGY



JOURNAL OF CASE REPORTS AND IMAGES IN
DENTISTRY



EDORIUM JOURNAL OF
CANCER



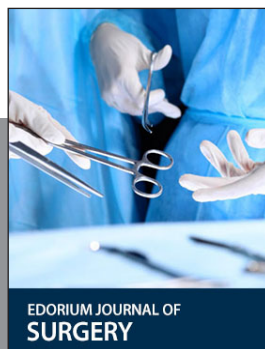EDORIUM JOURNAL OF
PSYCHIATRY



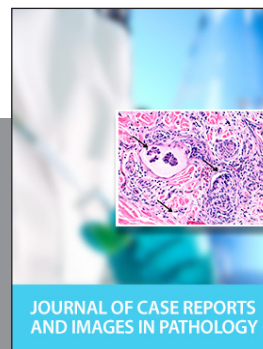
JOURNAL OF CASE REPORTS AND
IMAGES IN INFECTIOUS DISEASES



EDORIUM JOURNAL OF
ANATOMY AND EMBRYOLOGY



EDORIUM JOURNAL OF
SURGERY



JOURNAL OF CASE REPORTS
AND IMAGES IN PATHOLOGY



EDORIUM JOURNAL OF
ANESTHESIA