

Two true umbilical knots with good fetal outcome: A case report

Malachy Nwaeze Ezenwaeze, Sylvester Onuegbunam Nweze,
Boniface Uwaezuoke Odugu, Ifeanyi Ofor,
Obumneme Nkemakonam Chukwubuike, Chibugo Ndidiamaka Ezenwaeze

ABSTRACT

True knot of the umbilical cord is a rare occurrence with 4–10 fold increased risk of stillbirth. Infants with umbilical cord true knots often suffer extents of hypoxia in their prenatal course, which may cause fetal distress or even intrauterine death. We report a rare case of two true knots of the umbilical cord that was observed in a very stable male fetus following caesarean delivery for breech presentation. Even though prenatal diagnosis of a true umbilical cord knot could be difficult, we recommend high index of suspicion, routine Doppler study of the umbilical cord especially in patients at risk of true knot formation and adequate intrapartum monitoring to ensue good pregnancy outcome.

Keywords: Caesarean delivery, Good fetal outcome, True knots, Umbilical cord

How to cite this article

Ezenwaeze MN, Nweze SO, Odugu BU, Ofor I, Chukwubuike ON, Ezenwaeze CN. Two true umbilical knots with good fetal outcome: A case report. J Case Rep Images Obstet Gynecol 2022;8:100113Z08ME2022.

Article ID: 100113Z08ME2022

doi: 10.5348/100113Z08ME2022CR

Malachy Nwaeze Ezenwaeze¹, Sylvester Onuegbunam Nweze², Boniface Uwaezuoke Odugu², Ifeanyi Ofor³, Obumneme Nkemakonam Chukwubuike⁴, Chibugo Ndidiamaka Ezenwaeze⁵

Affiliations: ¹Senior Registrar, Obstetrics and Gynaecology, ESUT Teaching Hospital, Enugu, Enugu State, Nigeria; ²Consultant Obstetrician and Gynaecologist, ESUT Teaching Hospital, Enugu, Enugu State, Nigeria; ³Fellow WACS, Obstetrics and Gynaecology, ESUT Teaching Hospital, Enugu, Enugu State, Nigeria; ⁴Registrar, Obstetrics and Gynaecology, ESUT Teaching Hospital, Enugu, Enugu State, Nigeria; ⁵Registrar, Paediatrics, University of Nigeria Teaching Hospital, Ituku-Ozalla, Enugu State, Nigeria.

Corresponding Author: Malachy Nwaeze Ezenwaeze, Enugu, Enugu State, Nigeria; Email: malachy.ezenwaeze@esut.edu.ng

Received: 04 December 2021

Accepted: 09 February 2022

Published: 28 April 2022

INTRODUCTION

True knot of the umbilical cord usually follows fetal passage through a loop of a cord. It is a rare occurrence [1], with 4–10 fold increased risk of stillbirth [2].

Single true knot of the umbilicus is very rare and the incidence is documented to be between 0.3% and 2% of pregnancies. The findings of two (2) true knots in the umbilical cord of our index case with good fetal outcome are more astonishing because any form of disorder in the umbilical cord can be life-threatening to the fetus.

It is generally considered that true knots of the umbilical cord occur in early gestation (between 9 and 12 weeks) when the overall amniotic fluid volume is considerably larger than the fetus [3].

Predisposing factors in the formation of true knots of the umbilical cord include: long umbilical cords, polyhydramnios, excessive fetal movements, gestational diabetes, multiparity, male fetus, small sized fetus, chronic hypertension [4], and interestingly, patients who have undergone genetic amniocentesis [5]. Generally, the average length of the umbilical cord is about 55 cm, and any length more than 80 cm is

regarded to be unduly long and capable of causing cord entanglement [2].

Wharton's jelly ordinarily surrounds the umbilical cord and reduces the probability of collapse of vessels. In event of loss of this protection as noted with true knots, the umbilical cord may tighten leading to decrease or abrupt cessation of blood flow resulting to intrauterine fetal demise [6, 7]. In Nnamdi Azikiwe University Teaching Hospital Newwi, South-East Nigeria, a case of true single umbilical knot leading to fetal demise was reported [8].

Here, we present a case of a male fetus that had a good outcome following caesarean delivery on account of frank breech presentation with an incidental finding of two true knots in the umbilical cord that measured 110 cm.

CASE REPORT

Our patient is Mrs. M.A, a booked 22-year-old G2p1A1. Her last normal menstrual period was on 28th November, 2020 and based on her regular 28th day cycle and non-use of hormonal oral contraceptive, her expected date of delivery (EDD) was on 5th September, 2021.

Pregnancy was desired, spontaneously conceived and confirmed with an abdominal ultrasound. She booked for antenatal care in ESUT Teaching Hospital at a gestational age of 12 weeks, prior to booking and at booking she had no complaint. Her booking weight was 70 kg, height was 1.6 m, and blood pressure was 110/70 mmHg. Her Hepatitis B surface antigen (HBsAg), venereal disease research laboratory (VDRL), and human immunodeficiency virus (HIV) 1 and 2 tests were not reactive. Her blood group was O Rhesus D positive, hemoglobin genotype was AA, and packed cell volume was 34%. She slept under insecticide treated net, was compliant with her routine antenatal drugs, and received two doses each of intermittent preventive therapy for malaria and tetanus toxoid at 22 and 26 weeks of gestation respectively. She was not a known hypertensive or diabetic patient and pregnancy progressed uneventfully until at 36 weeks when it was noted that her fetus was in breech presentation and routine 36 weeks ultrasound confirmed frank breech presentation of the fetus. She was subsequently counseled on options of management of her condition. She chose an elective caesarean delivery which she had at 38 completed weeks of gestation. The outcome was a live male neonate who cried immediately with Apgar scores of 8 and 10 in the 1st and 5th minutes of live respectively, birth weight was 3.4 kg.

Unsuspected findings of two (2) true knots of the umbilicus at 6 cm apart were noted 9 cm distal to cord attachment to the fetus (Figure 1). The umbilical cord length was measured and found to be 110 cm; no other fetal anomaly was noted. Baby remained stable postpartum without any reason for neonatal intensive care unit admission or institution of any medical treatment (Figure 2).

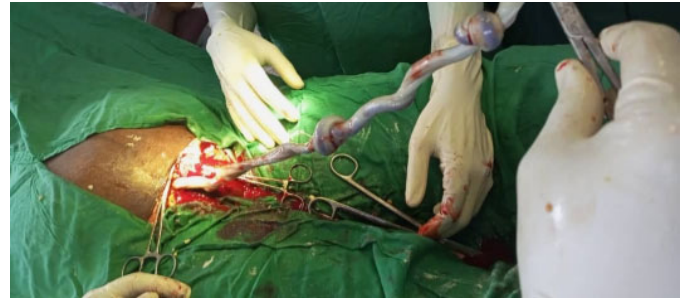

Figure 1: Two true umbilical knots.

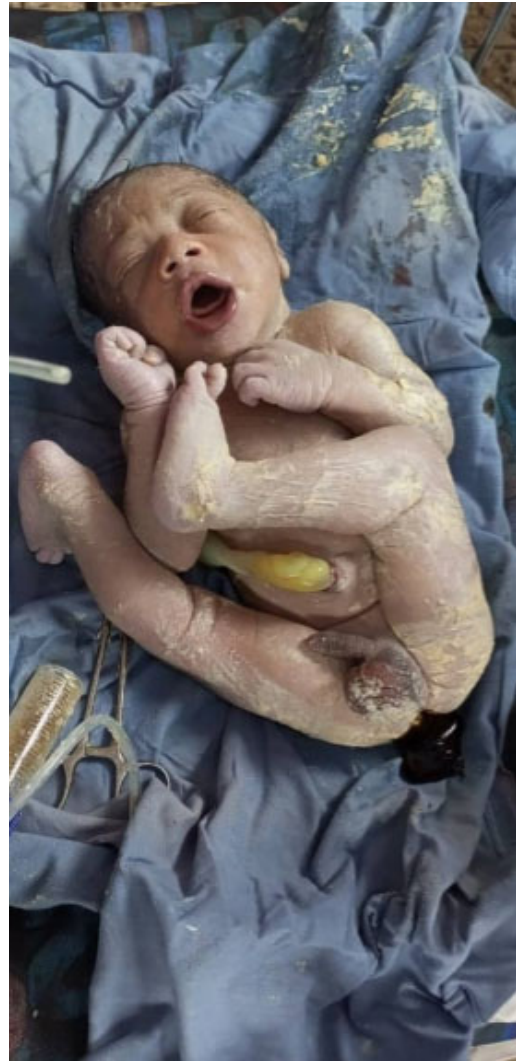

Figure 2: Stable male fetus.

DISCUSSION

True knots of the umbilicus are more likely to be detected when they are checked for especially when risk factors exist [9, 10]. Specifically, 4-dimensional color Doppler and power Doppler examination are the most important modalities for assessment and diagnosis of true knot [11]. Cloverleaf pattern [7] or hanging noose [2] may be seen incidentally.

Hence, scholars suggest that effort at prenatal diagnosis should be made especially when the suspicion or risk factor for the diagnosis exist [12].

Our patient had prenatal ultrasound investigation during antenatal care visits and at 36 weeks gestation, however the knots were missed.

Díaz de la Noval et al. observed that prenatal diagnosis of true knot umbilical cord is an exceptional and unexpected event that shouldn't change planned obstetric approach [7].

However, other researchers consider caesarean delivery more appropriate to ensure good outcome [10]. They argued that in the course of labor and passage of fetus through the birth canal, the knots can tighten and fetal circulation may be compromised [9].

Our patient was offered caesarean delivery on account of frank breech presentation with an incidental finding of two true knots. This intervention (caesarean delivery) may be responsible for the good fetal outcome observed.

CONCLUSION

Given the association of true knot of the umbilical cord and 4–10 fold increased risk of stillbirth, high index of suspicion, routine Doppler study of the umbilical cord especially in patient with high risk of true knot formation and adequate intrapartum monitoring are recommended to avert disservice to our patients and their fetuses.

REFERENCES

1. Airas U, Heinonen S. Clinical significance of true umbilical knots: A population-based analysis. *Am J Perinatol* 2002;19(3):127–32.
2. Sherer DM, Amoabeng O, Dryer AM, Dalloul M. Current perspectives of prenatal sonographic diagnosis and clinical management challenges of true knot of the umbilical cord. *Int J Womens Health* 2020;12:221–33.
3. Hershkovitz R, Silberstein T, Sheiner E, et al. Risk factors associated with true knots of the umbilical cord. *Eur J Obstet Gynecol Reprod Biol* 2001;98(1):36–9.
4. Suzuki S. Excessively long umbilical cord: A preventive factor of miserable outcomes of pregnancies with true umbilical cord knots. *J Matern Fetal Neonate Med* 2020;33(22):3757–60.
5. Linde LE, Rasmussen S, Kessler J, Ebbing C. Extreme umbilical cord lengths, cord knot and entanglement: Risk factors and risk of adverse outcomes, a population-based study. *PLoS One* 2018;13(3):e0194814.
6. Khan M, Zahiruddin S, Iftikhar M. True knot of umbilical cord: Case report and review of literature. *J Pak Med Assoc* 2016;66(8):1037–8.
7. Díaz de la Noval B, Llaneza IP, Sepúlveda MR, Barriados FJF, Blanco CF. True umbilical cord knot, an emergency during labor. *Clin Case Rep* 2019;7(11):2242–4.
8. Ikechebelu J, Eleje G, Ofojebe C. True umbilical cord knot leading to fetal demise. *Ann Med Health Sci Res* 2014;4(Suppl 2):S155–8.
9. Ramón y Cajal CL, Martínez RO. Four-dimensional ultrasonography of a true knot of the umbilical cord. *Am J Obstet Gynecol* 2006;195(4):896–8.
10. Deutsch AB, Miller E, Spellacy WN, Mabry R. Ultrasound to identify cord knotting in monoamniotic monochorionic twins. *Twin Res Hum Genet* 2007;10(1):216–8.
11. Hayes DJL, Warland J, Parast MM, et al. Umbilical cord characteristics and their association with adverse pregnancy outcomes: A systematic review and meta-analysis. *PLoS One* 2020;15(9):e0239630.
12. True knot of umbilical cord. 2019. [Available at: <https://www.dovemed.com/diseases-conditions/true-knot-umbilical-cord/>]

Acknowledgments

The authors wish to appreciate other doctors who played some roles in writing up this manuscript.

Author Contributions

Malachy Nwaeze Ezenwaeze – Conception of the work, Design of the work, Drafting the work, Revising the work critically for important intellectual content, Final approval of the version to be published, Agree to be accountable for all aspects of the work in ensuring that questions related to the accuracy or integrity of any part of the work are appropriately investigated and resolved

Sylvester Onuegbunam Nweze – Design of the work, Revising the work critically for important intellectual content, Final approval of the version to be published, Agree to be accountable for all aspects of the work in ensuring that questions related to the accuracy or integrity of any part of the work are appropriately investigated and resolved

Boniface Uwaezuoke Odugu – Design of the work, Drafting the work, Revising the work critically for important intellectual content, Final approval of the version to be published, Agree to be accountable for all aspects of the work in ensuring that questions related to the accuracy or integrity of any part of the work are appropriately investigated and resolved

Ifeanyi Ofor – Conception of the work, Drafting the work, Revising the work critically for important intellectual content, Final approval of the version to be published, Agree to be accountable for all aspects of the work in ensuring that questions related to the accuracy or integrity of any part of the work are appropriately investigated and resolved

Obumneme Nkemakonam Chukwubuike – Design of the work, Drafting the work, Final approval of the version to be published, Agree to be accountable for all aspects of the work in ensuring that questions related to the accuracy or integrity of any part of the work are appropriately investigated and resolved

Chibugo Ndidiamaka Ezenwaeze – Conception of the work, Design of the work, Drafting the work, Final approval of the version to be published, Agree to be accountable for all aspects of the work in ensuring that questions related to the accuracy or integrity of any part of the work are appropriately investigated and resolved

Guarantor of Submission

The corresponding author is the guarantor of submission.

Source of Support

None.

Consent Statement

Written informed consent was obtained from the patient for publication of this article.

Conflict of Interest

Authors declare no conflict of interest.

Data Availability

All relevant data are within the paper and its Supporting Information files.

Copyright


© 2022 Malachy Nwaeze Ezenwaeze et al. This article is distributed under the terms of Creative Commons Attribution License which permits unrestricted use, distribution and reproduction in any medium provided the original author(s) and original publisher are properly credited. Please see the copyright policy on the journal website for more information.

Access full text article on
other devices



Access PDF of article on
other devices





INTERNATIONAL JOURNAL OF CASE REPORTS AND IMAGES



VIDEO JOURNAL OF CLINICAL RESEARCH



VIDEO JOURNAL OF BIOMEDICAL SCIENCE



INTERNATIONAL JOURNAL OF HEPATOBILIARY AND PANCREATIC DISEASES




INTERNATIONAL JOURNAL OF BLOOD TRANSFUSION AND IMMUNOHEMATOLOGY



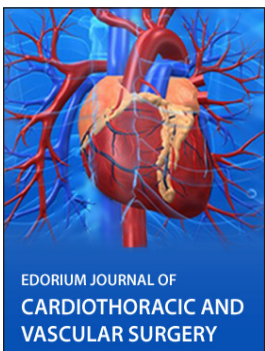EDORIUM JOURNAL OF OPHTHALMOLOGY



Submit your manuscripts at
www.edoriumjournals.com



EDORIUM JOURNAL OF MEDICINE



EDORIUM JOURNAL OF CARDIOTHORACIC AND VASCULAR SURGERY



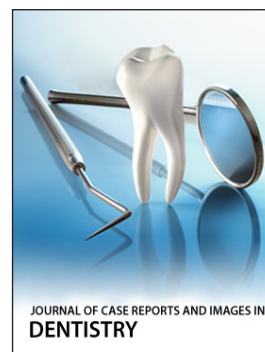JOURNAL OF CASE REPORTS AND IMAGES IN ORTHOPEDICS AND RHEUMATOLOGY



EDORIUM JOURNAL OF PSYCHOLOGY



EDORIUM JOURNAL OF CELL BIOLOGY



JOURNAL OF CASE REPORTS AND IMAGES IN DENTISTRY



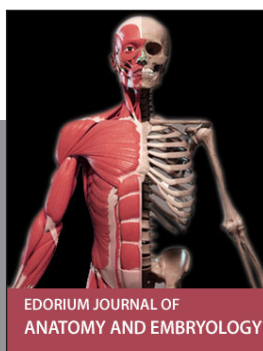EDORIUM JOURNAL OF CANCER



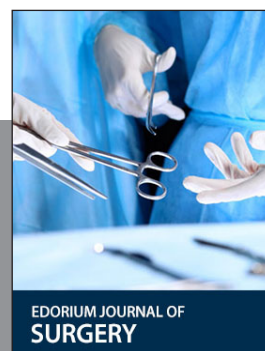
EDORIUM JOURNAL OF PSYCHIATRY



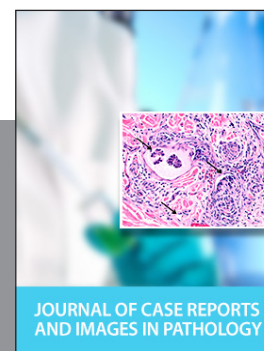JOURNAL OF CASE REPORTS AND IMAGES IN INFECTIOUS DISEASES



EDORIUM JOURNAL OF ANATOMY AND EMBRYOLOGY



EDORIUM JOURNAL OF SURGERY



JOURNAL OF CASE REPORTS AND IMAGES IN PATHOLOGY



EDORIUM JOURNAL OF ANESTHESIA