

CASE REPORT

PEER REVIEWED | OPEN ACCESS

Case of deep infiltrating and cystic endometriosis in a patient with a Müllerian anomaly: Surgical treatment by removing non-communicating horn

Tanne Daniels, Kaat Moelans, Jasper Verguts, Jurgen Bielen

ABSTRACT

Introduction: Endometriosis has a higher incidence in patients with Müllerian anomalies due to the increased likelihood of retrograde menstruation. This case presents unique challenges due to the diverse morphologies seen in Müllerian anomalies. Therefore, accurate and timely preoperative diagnosis is essential to optimize pain management and fertility outcomes.

Case Report: This case report presents the case of a 31-year-old patient with grade 4 endometriosis and a Müllerian anomaly, which resulted in the surgical treatment of the non-communication horn as well as the diseased ovary.

Conclusion: This case exemplifies the challenges seen in with Müllerian anomaly-associated endometriosis, such as diagnostic delay and intricacy of surgical treatment options. This case highlights the importance of early intervention and a multidisciplinary approach. Increased awareness of endometriosis in patients with Müllerian anomalies among healthcare providers can improve outcomes and minimize complications.

Keywords: Cystic endometriosis, Endometriosis, Horn excision, Müllerian anomaly

How to cite this article

Daniels T, Moelans K, Verguts J, Bielen J. Case of deep infiltrating and cystic endometriosis in a patient with a Müllerian anomaly: Surgical treatment by removing non-communicating horn. J Case Rep Images Obstet Gynecol 2025;11(1):42–47.

Article ID: 100197Z08TD2025

doi: 10.5348/100197Z08TD2025CR

INTRODUCTION

Endometriosis is a common gynecological condition characterized by benign proliferation of endometrium-like tissue outside of the uterine cavity [1–3]. This ectopic tissue can be found on the ovaries, fallopian tubes, outer surface of the uterus, and other organs within the pelvis. Unlike the endometrial tissue within the uterus, which is shed during menstruation, this ectopic tissue can cause inflammation, scarring, and adhesions. This can lead to chronic pain, heavy periods, and fertility issues. The exact cause of endometriosis is not well understood, but it is believed to involve a combination of genetic, hormonal, immune, and environmental factors [4, 5].

Retrograde menstruation is thought to play a key role in the disease development [3, 4]. This retrograde flow of menstrual fluids facilitates spreading of endometrial tissue into the abdominal cavity. Retrograde menstruation can occur in healthy individuals but is more frequent in women with Müllerian anomalies. These uterine malformations occur in 0.2–5% of the female population and can result in obstructive or preserved outflow tracts [6]. However, this is not the only factor to be involved in the disease development of endometriosis. Pathophysiology believes that the disease is estrogen-dependent with the presence of estrogen receptors found in endometriosis tissue as well as an inflammatory disease [4].

Tanne Daniels¹, Kaat Moelans², Jasper Verguts³, Jurgen Bielen⁴

Affiliations: ¹Fellow Benign Gynecology and Endometriosis, Obstetrics and Gynecology, Jessa Hospital Hasselt, Hasselt, Belgium; ²Medical student, Obstetrics and Gynecology, Jessa Hospital Hasselt, Hasselt, Belgium; ³Gynecologist, Obstetrics and Gynecology, Jessa Hospital Hasselt, Hasselt, Belgium; ⁴Radiologist, Radiology Department, Jessa Hospital Hasselt, Hasselt, Belgium.

Corresponding Author: Tanne Daniels, Fellow Benign Gynecology and Endometriosis, Obstetrics and Gynecology, Jessa Hospital Hasselt, Hasselt, Belgium; Email: tannedaniels@hotmail.com

Received: 04 January 2025

Accepted: 12 February 2025

Published: 08 March 2025

The patient presented in this report was diagnosed with a unicornuate uterus and a left-sided rudimentary horn. Unicornuate uteruses occur in approximately 1 in 1000 to 1 in 5400 women, of which 74–90% have an associated rudimentary horn [7]. These patients are susceptible to gynecologic complications including premature birth and miscarriage, hematosalpinx, chronic pelvic pain, and endometriosis [8].

Retrospective studies showed high endometriosis rates in women with Müllerian anomalies. Due to retrograde menstruation, the correlation is significantly higher in case of obstructive uterine malformations. The presence of endometrium tissue in the rudimentary horn is another important factor. Endometriosis occurrence is considerably higher in patients with active endometrium in the non-communicating horn, compared to those without active endometrium. In addition, uterine malformations might also lead to impaired uterine peristalsis, causing retrograde flow regardless of outflow tract function [6, 9, 10]. In conclusion, the correlation between obstructive Müllerian anomalies and endometriosis might be explained by higher rates of retrograde menstruation.

The diagnosis of rudimentary horns is often delayed, due to the presence of normal menstruation from the unicornuate uterus, absent clinical manifestation, and difficult visualization on imaging. The gold standard for visualization of rudimentary uterine horns is magnetic resonance imaging (MRI). Importantly, MRI is helpful in determining whether the rudimentary horn contains functional endometrium. After diagnosis, resection of the rudimentary horn is the recommended treatment. This is thought to prevent further complications and improve fertility outcomes [7, 11–13].

We discuss the surgical management of this case, which included removal of the rudimentary horn and extensive endometriosis lesions.

CASE REPORT

We present a 31-year-old female who was evaluated at a primary care center following a two-week history of acute-onset lower abdominal pain. Initial imaging by pelvic ultrasound showed an endometrioma measuring 5 cm. Upon this finding, she was urgently referred to our center and began treatment with a combination contraceptive pill containing ethinyl estradiol and dienogest. She was seen in clinic two days later, with complaints including grade 3 dysmenorrhea, progressive lower abdominal pain, dyschezia, and progressive fatigue. The pain escalated in severity, leading to symptoms of nausea and dizziness, necessitating the use of multiple analgesics for relief (including tramadol). On clinical examination, the speculum assessment was unremarkable, with no nodules observed. Although vaginal palpation elicited pain, the overall findings were normal. On pelvic ultrasound scan a bicorn uterus was suspected with normal trilaminar endometrium in the right horn and an anechogenic intrauterine lesion with hyperechogenic borders. A homogenic ground glass

cyst was observed between both uterine horns. The cyst seemed fixed against the uterus and measured 6 cm in maximum diameter with a color score of 1. These findings were compatible with an endometrioma, originating from the left ovary. The right ovary was morphologically normal, but less mobile against the uterus. The anterior compartment appeared normal on ultrasound scan. The posterior compartment had a thickened left sacro-uterine ligament, without obvious deep infiltrating nodule.

The patient's medical history mentions a bicornuate uterus and a right-sided renal agenesis. Her gynecological history shows gravida 1, para 1, with a spontaneous conception after 1.5 years. The baby was delivered through cesarian section because of breech position. Upon presentation in our clinic, she expressed a persisting pregnancy wish.

Further investigations showed an anti-Müllerian hormone (AMH) value of 2.62 µg/L. An MRI scan was conducted as echographic evaluation of the posterior compartment was not optimal in the presence of the endometrioma and because of the higher probability of a deep infiltrating endometriosis lesions in the presence of an endometrioma.

Two weeks after the consultation in our center the patient referred to the emergency department because of acute on chronic pain. An abdominal ultrasound and computed tomography (CT) scan showed peritonitis, likely secondary to appendicitis. Upon these findings, urgent laparoscopic abdominal surgery was performed. Here, an inflamed appendix was observed, along with chocolate-brown fluid in the pelvic region (consistent with the rupture of an endometrioma). An appendectomy was performed and the pelvis was washed out. Histologically, endometriosis of the appendix was found, without signs of appendicitis.

The MRI scan showed a unicornuate uterus with dilatation of the hypotrophic, non-communicating left horn with blood pooling (Figure 1A and B). It also showed a right tubo-ovarian complex with a likely endometrioma with recent blood. On the left side a large tubo-ovarian complex with hematosalpinx with large endometrioma (5.5 cm) and encapsulated serosanguinous fluid adjacent to the ovary could be seen. The sacro-uterine ligaments were bilaterally thickened with underlying cysts right paramedian, extending to the adjacent wall of the distal sigmoid with no deep bowel infiltration (Figure 2).

The case, together with MRI findings, was discussed at the multidisciplinary endometriosis meeting. This team of medical experts consists of gynecologists, radiologists, abdominal surgeons, urologists, as well as sexologists and fertility doctors. We decided on treatment by surgical removal of the left rudimentary horn along with the excision of endometriosis lesions. The distance between the two horns appeared sufficient to safely remove the left horn. We planned for preoperative stenting of the ureter since she had a single kidney. Due to the extent of the disease, the surgery was planned to be performed robotically.

Perioperatively, we found a large tubo-ovarian complex (endometrioma with large hematosalpinx) on the left side, adjacent to the ovarian fossa. The right horn of the uterus appeared normal, as well as the right tubo-ovarian complex, apart from superficial ovarian endometriosis lesions. The rectosigmoid was folded over this complex and the right horn of the uterus. The upper abdomen appeared to be free of endometriosis lesions. At the start of the surgery the non-communicating left horn was not visible. We began with extensive adhesiolysis of the rectosigmoid, which proceeded without complications. After the adhesiolysis the non-communicating left horn became visible.

We proceeded to remove the left tubo-ovarian complex, as there was no visible normal ovarian tissue remaining. If diagnosed earlier there would have been a possibility to save the ovary; however, this is hard to say. Following this, the rudimentary left horn was excised. Additionally, a recto-vaginal nodule without bowel or vaginal infiltration was removed, resulting in a stage 4 AFS endometriosis level. The left lateral incision was broadened to remove the specimen. The ureter stent was removed during the same operation.

The immediate postoperative recovery was uncomplicated, and the patient was able to leave the hospital the next day. She was advised to use a hormonal contraceptive until three months postoperatively. After this period, she may try to conceive again.

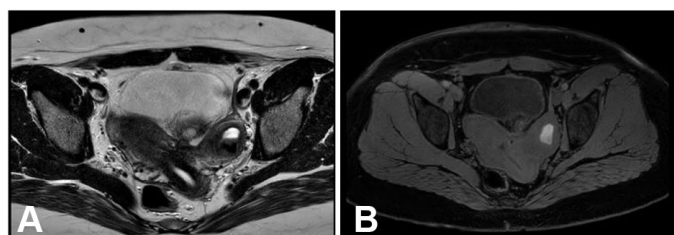


Figure 1: (A and B) T2 and T1 MRI image of the congenital anomaly with a unicornuate uterus (right cavity normal) and a hypoplastic, non-communicating left horn; dilation of the left horn containing blood. Discrete hemorrhagic endometriosis foci adjacent to the serosa on the left.

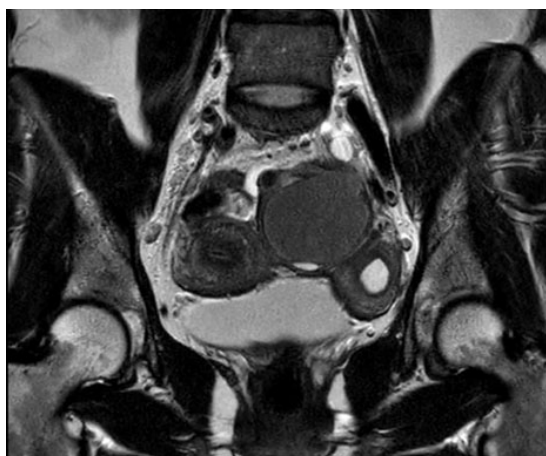


Figure 2: T2 MRI image of the two horns of the uterus with the left ovary endometrioma in between.

At the six-week postoperative follow-up consultation, she showed favorable recovery, with satisfactory healing of incision sites and no signs of recurrence on transvaginal ultrasound. Because of her persistent pregnancy wish, she decided against using contraceptives after the procedure. Luckily, an active cycle with a dominant follicle on the right ovary were established on ultrasound imaging.

DISCUSSION

According to the literature, approximately 75% of women with a uterine malformation also have endometriosis [6, 14], which is significantly higher than the estimated 10% prevalence in the general population [15–17]. Additionally, the association between uterine malformations and infertility may exacerbate the severity of endometriosis, highlighting the importance of accurate diagnosis and effective management [9].

In this case the diagnosis of a Müllerian anomaly was made before the patient's first pregnancy, but no link was made with the possibility of the presence of endometriosis. She reported to the general practitioner and gynecologist multiple times with complaints of dysmenorrhea and lower abdominal pain, but no diagnosis was made. She was finally diagnosed after the presence of a large endometrioma was seen following an acute on chronic abdominal pain episode for which she presented to the emergency department. This resulted in a diagnostic delay for this patient of about five years, which is consistent with literature [18].

The increased prevalence of endometriosis in patients with Müllerian anomalies is well documented. Additionally, ipsilateral renal agenesis has been associated with Müllerian anomalies and, consequently, endometriosis [19].

As retrograde menstruation plays a big role in the pathogenesis of endometriosis in these patients, early diagnosis and surgical management are crucial for the prevention of endometriosis lesions [6, 8, 9, 14, 19].

In the latest systemic review by Abboud et al. it is stated that laparoscopic removal of the rudimentary horn should be considered as a therapeutic option [11]. This case report underscores the importance of surgically removing the rudimentary horn in treating endometriosis when symptoms arise from retrograde menstruation. Without this intervention, the disease is more likely to recur.

With this case report we want to underline the importance of correct preoperative imaging, including MRI, for the specifications according the Müllerian anomaly. Furthermore, a multidisciplinary approach should be favored to thoroughly estimate the best possible surgical treatment. In patients with known Müllerian anomalies physicians should be vigilant of the possibility of the presence of endometriosis, especially with subsequent complaints.

CONCLUSION

This case report exemplifies the challenges seen in with Müllerian anomaly-associated endometriosis, such as diagnostic delay and intricacy of surgical treatment options. This case highlights the importance of early intervention and a multidisciplinary approach. Increased awareness of endometriosis in patients with Müllerian anomalies among healthcare providers can improve outcomes and minimize complications.

REFERENCES

1. Patel BG, Lenk EE, Lebovic DI, Shu Y, Yu J, Taylor RN. Pathogenesis of endometriosis: Interaction between endocrine and inflammatory pathways. *Best Pract Res Clin Obstet Gynaecol* 2018;50:50–60.
2. Parasar P, Ozcan P, Terry KL. Endometriosis: Epidemiology, diagnosis and clinical management. *Curr Obstet Gynecol Rep* 2017;6(1):34–41.
3. Ahn SH, Monsanto SP, Miller C, Singh SS, Thomas R, Tayade C. Pathophysiology and immune dysfunction in endometriosis. *Biomed Res Int* 2015;2015:795976.
4. Kitawaki J, Kado N, Ishihara H, Koshihara H, Kitaoka Y, Honjo H. Endometriosis: The pathophysiology as an estrogen-dependent disease. *J Steroid Biochem Mol Biol* 2002;83(1–5):149–55.
5. Czyzyk A, Podfigurna A, Szeliga A, Meczekalski B. Update on endometriosis pathogenesis. *Minerva Ginecol* 2017;69(5):447–61.
6. Piriye E, Römer T. Coincidence of uterine malformations and endometriosis: A clinically relevant problem? *Arch Gynecol Obstet* 2020;302(5):1237–41.
7. McCracken K, Hertweck SP. Noncommunicating rudimentary uterine horns. In: Pfeifer S, editor. *Congenital Müllerian Anomalies*. Cham: Springer International Publishing; 2016. p. 119–32.
8. Pitot MA, Bookwalter CA, Dudiak KM. Müllerian duct anomalies coincident with endometriosis: A review. *Abdom Radiol (NY)* 2020;45(6):1723–40.
9. Boujenah J, Salakos E, Pinto M, et al. Endometriosis and uterine malformations: Infertility may increase severity of endometriosis. *Acta Obstet Gynecol Scand* 2017;96(6):702–6.
10. Freytag D, Mettler L, Maass N, Günther V, Alkatout I. Uterine anomalies and endometriosis. *Minerva Med* 2020;111(1):33–49.
11. Abboud K, Giannini A, D’Oria O, et al. Laparoscopic management of rudimentary uterine horns in patients with unicornuate uterus: A systematic review. *Gynecol Obstet Invest* 2023;88(1):1–10.
12. Shukunami K, Tsunezawa W, Kotsuji F. Unicornuate uterus with a noncommunicating cavitary, laterally dislocated rudimentary horn presenting with adenomyosis, associated with ipsilateral renal agenesis. *Arch Gynecol Obstet* 2000;264(2):88–9.
13. Osnytska Y, Stojko R, Drosdzol-Cop A. The 18-year-old-girl with unicornuate uterus and endometriosis. *Ginekol Pol* 2024;95(2):167–8.
14. Kapczuk K, Friebe Z, Iwaniec K, Kędzia W. Obstructive Müllerian anomalies in menstruating adolescent girls: A report of 22 cases. *J Pediatr Adolesc Gynecol* 2018;31(3):252–7.

15. Becker CM, Bokor A, Heikinheimo O, et al. ESHRE guideline: Endometriosis. *Hum Reprod Open* 2022;2022(2):hoac009.
16. Kuznetsov L, Dworzynski K, Davies M, Overton C; Guideline Committee. Diagnosis and management of endometriosis: Summary of NICE guidance. *BMJ* 2017;358:j3935.
17. Moradi Y, Shams-Beyranvand M, Khateri S, et al. A systematic review on the prevalence of endometriosis in women. *Indian J Med Res* 2021;154(3):446–54.
18. Horne AW, Missmer SA. Pathophysiology, diagnosis, and management of endometriosis. *BMJ* 2022;379:e070750.
19. Yu BR, Chae HS, Rheu CH. Early-onset severe ovarian endometriosis in adolescents with completely obstructed Müllerian anomalies accompanied by ipsilateral renal agenesis: Two case reports. *J Surg Case Rep* 2024;2024(5):rjae272.

Author Contributions

Tanne Daniels – Conception of the work, Design of the work, Acquisition of data, Analysis of data, Interpretation of data, Drafting the work, Final approval of the version to be published, Agree to be accountable for all aspects of the work in ensuring that questions related to the accuracy or integrity of any part of the work are appropriately investigated and resolved

Kaat Moelans – Conception of the work, Revising the work critically for important intellectual content, Final approval of the version to be published, Agree to be accountable for all aspects of the work in ensuring that questions related to the accuracy or integrity of any part of the work are appropriately investigated and resolved

Jasper Verguts – Interpretation of data, Revising the work critically for important intellectual content, Final approval of the version to be published, Agree to be accountable for all aspects of the work in ensuring that questions related to the accuracy or integrity of any part of the work are appropriately investigated and resolved

Jurgen Bielen – Interpretation of data, Revising the work critically for important intellectual content, Final approval of the version to be published, Agree to be accountable for all aspects of the work in ensuring that questions related to the accuracy or integrity of any part of the work are appropriately investigated and resolved

Guarantor of Submission

The corresponding author is the guarantor of submission.

Source of Support

None.

Consent Statement

Written informed consent was obtained from the patient for publication of this article.

Conflict of Interest

Authors declare no conflict of interest.

Data Availability


All relevant data are within the paper and its Supporting Information files.

Copyright


© 2025 Tanne Daniels et al. This article is distributed under the terms of Creative Commons Attribution License which permits unrestricted use, distribution and reproduction in any medium provided the original author(s) and original publisher are properly credited. Please see the copyright policy on the journal website for more information.

ABOUT THE AUTHORS


Article citation: Daniels T, Moelans K, Verguts J, Bielen J. Case of deep infiltrating and cystic endometriosis in a patient with a Müllerian anomaly: Surgical treatment by removing non-communicating horn. J Case Rep Images Obstet Gynecol 2025;11(1):42–47.




Tanne Daniels is a gynecologist with a specific interest in endometriosis and benign gynecology. She earned her master's degree in medicine and specialistic medicine (Gynecology and Obstetrics) from the Catholic University in Leuven, Belgium. She pursued a fellowship in the field of endometriosis and benign gynecology at The Jessa Hospital in Hasselt, Belgium and is currently working in the endometriosis centre in the Jeroen Bosch in the Netherlands, where she provides care to patients dealing with endometriosis and collaborates on research aimed at improving treatment options. She has published 3 research papers in national and international academic journals.
Email: Tannedaniels@hotmail.com



Kaat Moelans is a medical student at the University of Gent with a specific interest in Gynaecology & Obstetrics. She is pursuing to become a gynecologist and plans to start her residency training in Switzerland after graduating.



Jasper Verguts is a gynecologist at Jessa Hospital in Hasselt, Belgium. He earned his master's degree in medicine and specialized medicine at the Catholic University of Leuven, Belgium. Afterward he continued with a doctoral degree in 2011 in the field of endoscopic surgery. He set up the endometriosis centre in Hasselt, where he provides care to patients dealing with endometriosis and collaborates on research aimed at improving treatment options of this condition. He has published diverse research papers in national and international academic journals and authored 1 book in the subject of endometriosis.



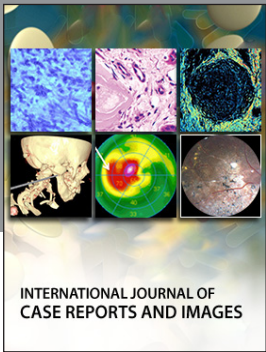
Jurgen Bielen is a radiologist in the Radiology Department at the Jessa Hospital in Hasselt, Belgium. He has a master's degree in medicine and civil engineering and subspecialized in the imaging of the abdomen. He is a profound member of the Multidisciplinary Endometriosis Team at Jessa Hospital, where he continues to provide care in patients dealing with this condition.

Access full text article on
other devices



Access PDF of article on
other devices





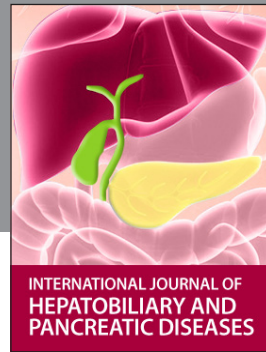INTERNATIONAL JOURNAL OF CASE REPORTS AND IMAGES



VIDEO JOURNAL OF CLINICAL RESEARCH



VIDEO JOURNAL OF BIOMEDICAL SCIENCE



INTERNATIONAL JOURNAL OF HEPATOBILIARY AND PANCREATIC DISEASES



INTERNATIONAL JOURNAL OF BLOOD TRANSFUSION AND IMMUNOHEMATOLOGY



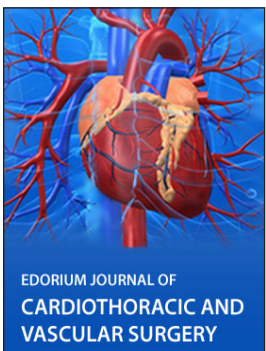
EDORIUM JOURNAL OF OPHTHALMOLOGY



Submit your manuscripts at
www.edoriumjournals.com



EDORIUM JOURNAL OF MEDICINE



EDORIUM JOURNAL OF CARDIOTHORACIC AND VASCULAR SURGERY



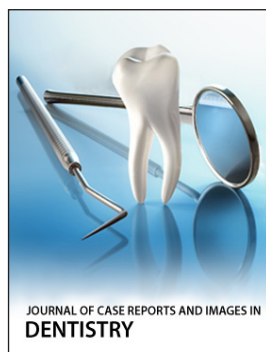
JOURNAL OF CASE REPORTS AND IMAGES IN ORTHOPEDICS AND RHEUMATOLOGY



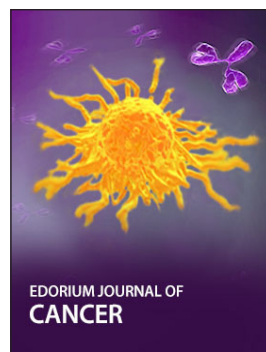EDORIUM JOURNAL OF PSYCHOLOGY




EDORIUM JOURNAL OF CELL BIOLOGY



JOURNAL OF CASE REPORTS AND IMAGES IN DENTISTRY



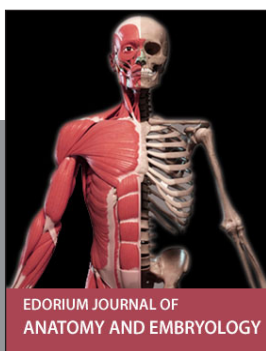EDORIUM JOURNAL OF CANCER



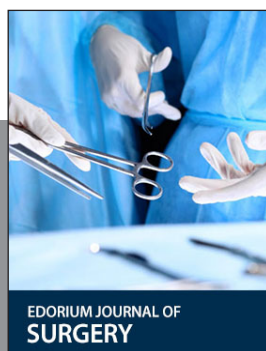
EDORIUM JOURNAL OF PSYCHIATRY



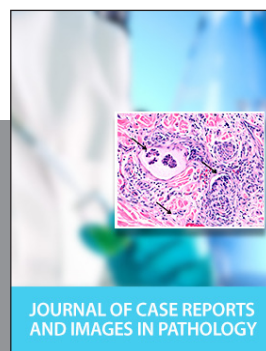JOURNAL OF CASE REPORTS AND IMAGES IN INFECTIOUS DISEASES



EDORIUM JOURNAL OF ANATOMY AND EMBRYOLOGY



EDORIUM JOURNAL OF SURGERY



JOURNAL OF CASE REPORTS AND IMAGES IN PATHOLOGY



EDORIUM JOURNAL OF ANESTHESIA