EDORIUM Journals

J Case Rep Images Obstet Gynecol 2026 Jul-Dec;12(2):42–44.
www.ijcriog.com

CLINICAL IMAGE PEER REVIEWED | OPEN ACCESS

Isolated fallopian tube torsion

Dynora Pierre-Louis, Iliza Minaya, Jordan Taylor-Bentley, Benjamin L Davis, Jose Luis Terrazas

CASE REPORT

A 33-year-old G2P0020 with a history of an appendectomy presented to the emergency department with complaints of acute right lower quadrant abdominal and pelvic pain. The patient described the pain as 10 out of 10 in severity, constant, worsening when lying flat and improving when sitting upright or leaning forward. On physical examination, the abdomen was soft with right lower quadrant tenderness to palpation and right flank pain without evidence of peritoneal signs. The patient reported her last menstrual period began six days prior to presentation. Laboratory findings were unremarkable, including a negative urine pregnancy test. Given the patient's acute right-sided abdominal pain and flank tenderness, computed tomography (CT) of the abdomen and pelvis was obtained in the emergency department to evaluate for suspected nephrolithiasis. Computed tomography imaging demonstrated no obstructive renal or ureteral calculi; however, a 4.9 cm pelvic cyst, possibly adnexal in origin, was identified. A pelvic ultrasound was subsequently performed and demonstrated normal bilateral ovarian blood flow and a 5 cm right simple cyst. Given persistent symptoms and the radiographic findings, there was concern for intermittent ovarian torsion. The patient was taken to the operating room for a diagnostic laparoscopy. Intraoperatively, a right paratubal cyst was identified, and the right fallopian tube was noted to be twisted several times around itself (Figure 1). The paratubal cyst was excised, and the fallopian tube was successfully detorsed without evidence of ischemic necrosis. The fallopian tube promptly reverted to normal color after detorsion (Figure 2). Both ovaries appeared normal. The patient's postoperative course was uncomplicated, with resolution of symptoms, and she was discharged home in stable condition.

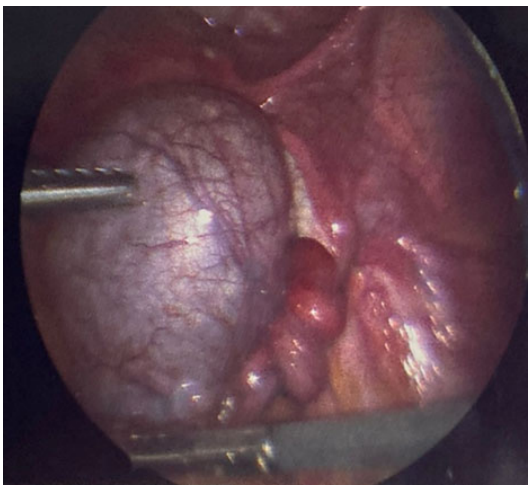

Figure 1: Intraoperative laparoscopic images. Right paratubal cyst and torsed right fallopian tube, Grade 1 ischemia.

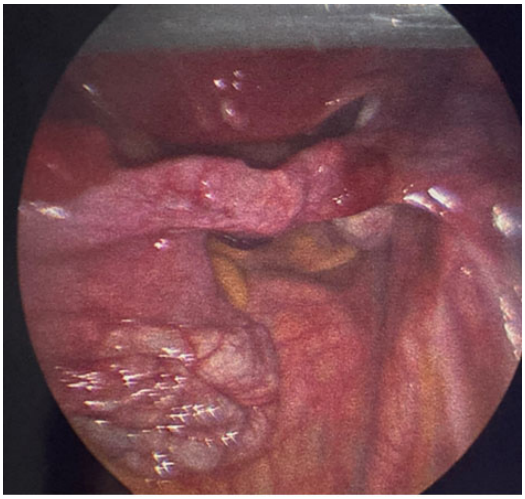

Figure 2: Intraoperative laparoscopic images. Right fallopian tube after detorsion and excision of right paratubal cyst.

Dynora Pierre-Louis[1], Iliza Minaya[1], Jordan Taylor-Bentley[2], Benjamin L Davis[3], Jose Luis Terrazas[4]

Affiliations: [1]MD, Resident Physician, Obstetrics and Gynecology, HCA East Florida Division Westside/Northwest, Margate, Florida, USA; [2]3rd year medical student, Dr. Kiran C. Patel College of Allopathic Medicine, Davie, Florida, USA; [3]DO, Physician, Obstetrics and Gynecology, HCA East Florida Division Westside/Northwest, Margate, Florida, USA; [4]MD, Physician, Obstetrics and Gynecology, HCA East Florida Division Westside/Northwest, Margate, Florida, USA.

Corresponding Author: Dynora Pierre-Louis, 4176 Derby Drive, Davie, FL 33330, USA; Email: pierrelouis.dynora@gmail.com

Received: 30 April 2026
Accepted: 16 July 2026
Published: 11 November 2026

DISCUSSION

Isolated fallopian tube torsion (IFTT) is a rare gynecological emergency affecting 1 in 1.5 million reproductive-aged women [1]. It is characterized by the twisting of the fallopian tube [2]. Patients often present with nonspecific symptoms (i.e., acute intermittent lower abdominal/pelvic pain, nausea, and vomiting), leading to concern for more commonly presented emergencies such as an ectopic pregnancy, ovarian torsion, ruptured ovarian cysts, pelvic inflammatory disease, tubo-ovarian abscess, appendicitis and intestinal obstruction/perforation [3].

Risk factors for IFTT include both (1) intrinsic factors (i.e., pelvic inflammatory disease, anatomical abnormalities—hydrosalpinx, hematosalpinx, long mesosalpinx, tubal ligation, physiologic abnormalities—tubal spasm, hypermotility of tube, and tubal neoplasm) and (2) extrinsic factors (i.e., adhesions, adnexal venous congestion, ovarian/paraovarian masses, uterine masses, gravid uterus, and trauma) [2, 3].

Fallopian tube torsion commonly affects the right tube. It is believed that this is because of (1) the right utero-ovarian ligament is longer than the left, which increases likelihood of torsion and (2) partial immobilization of the left tube due to its proximity to the sigmoid mesentery [3].

Diagnosis of an isolated tubal torsion is difficult because of the lack of specific radiologic findings. It is important to recognize the possibility of this diagnosis in the setting of acute pelvic pain in reproductive-aged women with a normal sonographic ovary, as delayed diagnosis and treatment may result in compromised fertility and increased morbidity. Definitive diagnosis can only be made at the time of surgery. Therefore, laparoscopy is both diagnostic and therapeutic as it allows for detorsion and potential preservation of the fallopian tube. If the fallopian tube appears necrotic, a salpingectomy may be required. The severity of ischemic necrosis can range from Grade 1, slightly discolored to Grade 4, completely black and necrotic [1]. Early surgical intervention is critical to prevent irreversible ischemic damage and to preserve fertility.

CONCLUSION

This case emphasizes the importance of considering isolated fallopian tube torsion in the differential diagnosis of acute pelvic pain, particularly in reproductive-aged women. It highlights the value of clinical presentation and intraoperative evaluation in establishing the diagnosis and guiding management. Early laparoscopic identification and intervention facilitate definitive diagnosis, maximize the potential for organ preservation, and improve patient outcomes.

REFERENCES

1. Balasubramaniam D, Duraisamy KY, Ezhilmani M, Ravi S. Isolated fallopian tube torsion: A rare twist with a diagnostic challenge that may compromise fertility. J Hum Reprod Sci 2020;13(2):162–7.
2. Varghese S, Seldon Y, Raperport C, Rinne N, Patel K, Zaid RZ. Isolated fallopian tube torsion: A systematic review of case reports. Eur J Obstet Gynecol Reprod Biol 2024;296:140–7.
3. Gross M, Blumstein SL, Chow LC. Isolated fallopian tube torsion: A rare twist on a common theme. AJR Am J Roentgenol 2005;185(6):1590–2.

Keywords: Adnexal torsion, Gynecologic emergency, Isolated fallopian tube torsion, Laparoscopic surgery, Ovarian torsion, Paratubal cyst

How to cite this article

Pierre-Louis D, Minaya I, Taylor-Bentley J, Davis BL, Terrazas JL. Isolated fallopian tube torsion. J Case Rep Images Obstet Gynecol 2026;12(2):42–44.

Article ID: 100243Z08DL2026

****

doi: 10.5348/100243Z08DL2026CI

****

Author Contributions

Dynora Pierre-Louis – Conception of the work, Design of the work, Acquisition of data, Drafting the work, Revising the work critically for important intellectual content, Final approval of the version to be published, Agree to be accountable for all aspects of the work in ensuring that questions related to the accuracy or integrity of any part of the work are appropriately investigated and resolved

Iliza Minaya – Interpretation of data, Revising the work critically for important intellectual content, Final approval of the version to be published, Agree to be accountable for all aspects of the work in ensuring that questions related to the accuracy or integrity of any part of the work are appropriately investigated and resolved

Jordan Taylor-Bentley – Interpretation of data, Drafting the work, Revising the work critically for important intellectual content, Final approval of the version to be published, Agree to be accountable for all aspects of the work in ensuring that questions related to the accuracy or integrity of any part of the work are appropriately investigated and resolved

Benjamin L Davis – Conception of the work, Acquisition of data, Revising the work critically for important intellectual content, Final approval of the version to be published, Agree to be accountable for all aspects of the work in ensuring that questions related to the accuracy or integrity of any part of the work are appropriately investigated and resolved

Jose Luis Terrazas – Conception of the work, Interpretation of data, Revising the work critically for important intellectual content, Final approval of the

version to be published, Agree to be accountable for all aspects of the work in ensuring that questions related to the accuracy or integrity of any part of the work are appropriately investigated and resolved

Guarantor of Submission
The corresponding author is the guarantor of submission.

Source of Support
None.

Consent Statement
Written informed consent was obtained from the patient for publication of this article.

Conflict of Interest
Authors declare no conflict of interest.

Data Availability
All relevant data are within the paper and its Supporting Information files.

Copyright
© 2026 Dynora Pierre-Louis et al. This article is distributed under the terms of Creative Commons Attribution License which permits unrestricted use, distribution and reproduction in any medium provided the original author(s) and original publisher are properly credited. Please see the copyright policy on the journal website for more information.

Access full text article on other devices

Access PDF of article on other devices







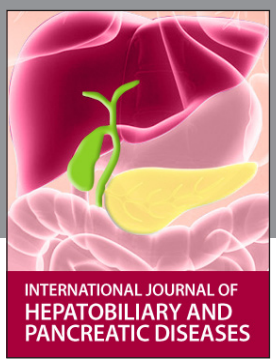





Submit your manuscripts at

www.edoriumjournals.com



